Chapter 40

DELAYED MANAGEMENT OF LARYNGOTRACHEAL TRAUMA

ROBERT L. ELLER, MD*; N. SCOTT HOWARD, MD†; AND ERIN HAMERSLEY, DO‡

INTRODUCTION

INJURY MECHANISMS
- **Acute Intubation-Related Injury**
- **Late Intubation-Related Injury**
- **Tracheotomy-Related Injury**

HISTORY, PHYSICAL EXAMINATION, AND INVESTIGATIONS
- **History**
- **Physical Examination**
- **Tests**

PATHOPHYSIOLOGY
- **Intubation-Related Injury**
- **Musculomembranous Vocal Fold Injuries**
- **Injuries Affecting Arytenoid Position**

SITE-SPECIFIC PROBLEMS AND THEIR MANAGEMENT
- **Supraglottic Stenosis**
- **Posterior Glottic Stenosis**
- **Glottic Webs**
- **Subglottic and Tracheal Stenosis**

OTHER CAUSES OF AIRWAY NARROWING
- **Tracheotomy-Related Granulation Tissue**
- **Lambdoid Tracheal Stenosis**
- **Tracheomalacia**
- **Suprastomal Collapse**

SUMMARY

CASE PRESENTATIONS
- **Case Study 40-1**
- **Case Study 40-2**
- **Case Study 40-3**
- **Case Study 40-4**
- **Case Study 40-5**

*Lieutenant Colonel, Medical Corps, US Air Force; Deputy Squadron Commander and Chief of Otolaryngology, PSC 41, Box 1275 APO AE, 09464 Royal Air Force Lakenheath, United Kingdom; Assistant Professor of Surgery, Uniformed Services University of the Health Sciences
†Lieutenant Colonel, Medical Corps, US Army; Chief, Otolaryngology, Head and Neck Surgery, San Antonio Military Medical Center, 3851 Roger Brook Drive, Fort Sam Houston, Texas 78234-6200; Assistant Professor of Surgery, Uniformed Services University of the Health Sciences
‡Lieutenant, Medical Corps, US Navy; Resident Physician, Otolaryngology Department, Portsmouth Naval Medical Center, 620 John Paul Jones Circle, Portsmouth, Virginia 23708-2197*

INTRODUCTION

The austere environment of war surgery requires rapid examination and initiation of lifesaving procedures in patients who are often multiply injured. A casualty may arrive at even the lowest role of care intubated thanks to the combat medic; however, this removes clues that would suggest a laryngeal injury during the physical exam. The endotracheal tube eliminates the problem caused by an injured larynx by securing the airway, and more visible or threatening injuries then take precedence.

While several surgical teams often intervene simultaneously at Role 3 facilities, all injuries are not always addressed in US personnel before the patient is evacuated to facilities offering definitive care. These polytrauma patients often need a secure airway prior to transportation in a cramped environment, and thus are either intubated or have a tracheotomy placed, which would not be necessary in a stable civilian tertiary care setting. It may therefore be months before a laryngeal injury is recognized. Injured troops may be told that voice difficulties are "just because of the breathing tube" and will get better with time. Others may not understand why they can't breathe well during rehabilitation sessions.

Considering these factors, war-related laryngotracheal injuries frequently fall into four categories:

1. known laryngeal injuries receiving initial management in theater and requiring follow-up in a definitive care setting;
2. known laryngeal injuries with no initial management due to emergent transportation;
3. iatrogenic injuries; or
4. unrecognized laryngeal injuries.

This chapter will explore combat-related laryngeal and airway trauma presenting to facilities offering definitive care, emphasizing techniques to diagnose and treat the problems.

INJURY MECHANISMS

The mechanisms of injury for external trauma are presented in detail in Chapter 29, Management of Acute Laryngeal Trauma. The techniques discussed in Chapter 29 are intended to prevent late complications.

Laryngeal injury may occur as a consequence of other lifesaving therapies. The most common cause of laryngeal injury is routine endotracheal intubation.

Acute Intubation-Related Injury

In patients with acute laryngeal trauma, translaryngeal intubation must be approached cautiously because it may result in further damage to or avulsion of endolaryngeal mucous membranes, the creation of pseudo-lumens, or disruption of an already tenuous airway, leading to respiratory arrest.[1] Even in routine situations, it is well documented that endotracheal intubation has a high risk of causing laryngeal injury. Up to 55% of uneventful intubations are associated with minor vocal fold injury that is measurable acoustically.[2] The injury is related to the tube itself in most cases, but the act of intubation can also injure the larynx, with mucosal lacerations, vocal fold hematoma, arytenoid dislocation, and paralysis. Risk and degree of injury increase with the degree of difficulty and the number of attempts prior to successful intubation. Additionally, the risks increase when less experienced personnel perform the intubation.

Late Intubation-Related Injury

Even after successful intubation with or without laryngeal trauma, patients remaining intubated are at risk for further laryngeal injury. Prolonged endotracheal intubation can damage the posterior glottis and the trachea and is the most common cause of acquired chronic airway stenosis. The risk of long-term injury from translaryngeal intubation varies from 10% to 22%; in 1% to 2% of cases, stenosis is severe enough to require intervention.[3] In 2010, House et al looked at 61 patients with prolonged intubation and found that all suffered some degree of laryngeal injury secondary to their intubation, including those intubated for only 48 hours.[4] The area most commonly injured in adults is the posterior endolarynx, and mucosal injury of the arytenoid and the interarytenoid area is the most frequent finding.[4,5] Traumatic intubation and the mere presence of a tube likely contribute to this injury.[5] Visible, if not symptomatic, intubation-related stenosis is reported in 10% of patients intubated for more than a week.[5] Softer endotracheal tube materials and efforts to perform early tracheotomy may reduce this risk.[6]

Translaryngeal intubation is also associated with vocal fold immobility. In a study including 31,241 patients, the incidence of vocal fold immobility was 0.077%. The risk doubled for patients intubated more than 2 hours, or who also had diabetes or hypertension. The risk tripled for patients over 50 years of age, and

there was a 15-fold increase in vocal fold immobility in patients intubated more than 6 hours.[7] Possible sequelae of intubation are listed in Exhibit 40-1.

EXHIBIT 40-1

INJURIES SEEN WITH INTUBATION LONGER THAN 48 HOURS

- Mucosal erythema and edema
- Vocal process ulcerations
- Interarytenoid webs
- Posterior glottic stenosis
- Glottic webs
- Vocal fold immobility
- Subglottic edema or stenosis
- Tracheal stenosis

Data sources: (1) Colton House J, Noordzij JP, Murgia B, Langmore S. Laryngeal injury from prolonged intubation: a prospective analysis of contributing factors. *Laryngoscope*. 2010;121(3):596–600. (2) Pfannenstiel TJ, Gal TJ, Hayes DK, Myers KV. Vocal fold immobility following burn intensive care. *Otolaryngol Head Neck Surg*. 2007;137:152–156. (3) Edwards J, Tanna N, Bielamowicz SA. Endoscopic lysis of anterior glottic webs and silicone keel placement. *Ann Otol Rhinol Laryngol*. 2007;116:211–216. (4) Sztano B, Szakacs L, Madani S, et al. Comparison of endoscopic techniques designed for posterior glottic stenosis—a cadaver morphometric study. *Laryngoscope*. 2014;124(3):705–710. (5) Benjamin B. Prolonged intubation injuries of the larynx: endoscopic diagnosis, classification, and treatment. *Ann Otol Rhinol Laryngol Suppl*. 1993;160:1–15.

Tracheotomy-Related Injury

Tracheotomy is often performed to reduce the risk of prolonged intubation or reduce risk of accidental extubation during air evacuation. Primary factors involved in the development of laryngeal stenosis are the duration of intubation and the size of the endotracheal tube (ETT).[8] No specific guidelines for duration of intubation in the combat theater have been established. However, several studies in adults have shown that after a 7- to 10-day period, prolongation of intubation is accompanied by increased incidence of laryngotracheal complications.[8] A 7-year, multiinstitutional, prospective, randomized trial of early versus late tracheotomy in 622 patients in the United Kingdom showed the complication rate for tracheotomy in the intensive care unit (ICU) or hospital to be 6.3%. The study was designed to show the effect of tracheotomy on the length of ICU stay and hospital stay and did not assess for differences in laryngeal injury or late complications of tracheotomy or intubation.[9]

A multiinstitutional study of tracheotomy in the United States did assess for late complications related to the procedure. The authors reviewed 1,175 tracheotomy patients over 2 years and documented intraoperative, early (<1 week), and late complication rates of 1.4%, 5.6%, and 7.1%, respectively. There was a 1.7% tracheal stenosis rate. Obesity (body mass index >30) and the use of ETTs larger than size 7.5 were identified as major risk factors for the development of airway stenosis. Obese patients with smaller tubes also had a higher rate of stenosis compared with non-obese patients, suggesting that obesity was both an independent and contributing risk factor for stenosis.[10] A similar overall rate of long-term complications associated with percutaneous dilational tracheotomy was 1.8% in a study from Germany.[11]

HISTORY, PHYSICAL EXAMINATION, AND INVESTIGATIONS

"The eye will not see what the mind does not know."
—Anonymous

The injury patterns from external trauma were discussed in Chapter 29, Management of Acute Laryngeal Trauma. Whether the acute trauma was blunt or penetrating, similar late problems can arise. The goal of acute management is to prevent or minimize chronic dysphonia, dysphagia, and stenosis. If the injury was severe, late management will be necessary even with expert acute care. If, as in the above quote, the acute injury was missed, the problem must first be "seen." The astute physician will combine elements of the remote history, current symptoms, and proper physical examination to "see" what is there. For most military otolaryngologists in garrison, this is the most important part of this chapter. A correct diagnosis leads to appropriate treatment or referral.

Patients with laryngotracheal problems can be brought to the otolaryngologist from almost any department: from the ICU after the patient fails extubation, from pulmonologists after an unusual pulmonary function test, from speech pathology after a swallowing evaluation, or from the astute primary physician who recognizes that the patient should be better. Because patients with laryngeal trauma (both combat-related and non-combat-related) usually have

other injuries or burns,[12,13] the other injuries may partially explain laryngeal or airway symptoms, and thus delay their investigation.

History

Voice Symptoms

Injury to the neuromuscular components or to the vocal folds themselves can cause changes in turbulence, valve competency, and musculomembranous pliability. Symptoms range from frank hoarseness to effortful phonation, loss of range, or vocal fatigue. Asking how and when the voice fails the patient, how long they can use it, and which situations degrade the voice can assist the surgeon in pinpointing the problem. Involving a good voice therapist to unload compensatory hypertension may be necessary to identify the underlying cause of the hoarseness.

Hyperfunctional Compensation

Organic problems of the voice frequently lead patients to compensate with hyperfunctional habits as they try to make a serviceable voice with a limited instrument. The most common example of this is the use of the ventricular folds for phonation (ie, plica ventricularis), frequently seen in patients who have had multiple laryngeal surgeries as children for airway stenosis.[14] When long-standing, these compensatory behaviors can lead to vocal process and arytenoid granuloma formation. Thus, when seeing a patient with muscle tension dysphonia or a granuloma, one should ask, "WHY does this patient have it?" The answer may be multifactorial; glottic insufficiency, vocal fold scar, and laryngopharyngeal reflux are common causes in this patient demographic. Posttraumatic stress disorder can also contribute to abnormal hyperfunction.

Airway Symptoms

Patients presenting with delayed airway injuries are often asymptomatic at rest, but airway limitations can become apparent during speech or exertion. As injuries progress through the phases of wound healing, airway narrowing may be associated either with exuberant granulation tissue or wound contracture. Obstructing lesions in the glottis, such as large posterior granulomas, affect both the voice and the breathing, whereas scar contracture, bilateral vocal fold paralysis, and tracheal lesions primarily affect breathing alone. Granulomas may evolve into scars.[15] An interarytenoid scar band may prevent abduction and impair breathing, but allow normal adduction. If the vocal folds can approximate and vibrate, the voice can be normal, even if there is significant stenosis. It is therefore critical to assess for full range of motion at the level of the vocal process.

Noisy breathing is often called "wheezing" by primary care doctors (who may see a thousand patients with asthma for every one with tracheal stenosis). A prolonged inspiratory phase is a clear indication of a problem, even if no stridor is evident. Isolated inspiratory stridor indicates a lesion between the glottis and supraglottis, biphasic stridor indicates a lesion between the subglottis and the thoracic inlet, and isolated expiratory stridor indicates an intrathoracic tracheal or bronchial lesion. Patients with airway limitations often complain that they cannot get their breath fast enough, but they can fill their lungs, while patients with lower airway disease complain they cannot get a big enough breath. Both problems can be exacerbated by the anxiety associated with the poor air exchange. Patients with slow progressive stenosis adapt amazingly well. An acute reduction of the airway from normal to 4 mm could be fatal, but a patient with a 4-mm chronic stenosis may walk into the physician's office without much difficulty.

Swallowing Symptoms

Neuromuscular injuries cause dysphagia when recurrent laryngeal nerve injury prevents appropriate valve closure of the larynx during swallowing, leading to dysphagia to liquids. This often improves with some compensation over a few weeks. For injuries that include the superior laryngeal nerve, sensory and motor changes result in pooling of saliva on the affected side, which then accumulates and can spill over the aryepiglottic fold, causing a chronic cough, throat clearing, and aspiration. Patients with thyroid cartilage cornua and hyoid bone fractures may have odynophagia, especially if non-union occurs.[16] This can be similar to hyoid syndrome or "click larynx," as described in recent reviews by Stern et al[17] and Smith et al.[18] Dysphagia can also be caused by surgical exploration along the constrictors causing injury to the pharyngeal plexus, and can present very similarly to the dysphagia seen after anterior cervical discectomy and fusion procedures with reduced constrictor muscular tone and poor coordination of the cricopharyngeus.[19]

Contributing Factors: General Medical Conditions and Reflux

Treatment must be individualized to each patient. A young soldier seeking to regain peak fitness will

have different airway needs than an elderly civilian in the host nation. Patients with comorbidities may need closer follow-up. For example, patients with diabetes mellitus had airway stenosis recurrence in an average period of 3.9 months, significantly faster than nondiabetic patients, who recurred on average in 10.5 months.[20] Pulmonary and cardiac problems often coincide and must be managed in conjunction with the airway pathology.

Gastroesophageal reflux disease (GERD) is a significant contributor to the severity of disease in the larynx and trachea. Maronian et al showed that there is a strong association of laryngopharyngeal reflux and subglottic stenosis, particularly when perichondrium and cartilage were violated from trauma with subsequent exposure to gastric acid.[21] They determined that surgical outcome is superior in patients with laryngopharyngeal reflux treated with antireflux medications compared to a control group. However, patient comorbidities such as diabetes and heart failure were found to have increased granulation tissue formation in both groups, suggesting that formation is multifactorial, with granulation exacerbated in the setting of laryngopharyngeal reflux.[22] Yellon et al studied the effect of reflux on subglottic stenosis. They found that the resulting stenosis, mucosal ulceration, and epithelial basal cell hyperplasia was exacerbated by the presence of gastric acid.[23] Therefore, definitive diagnosis and treatment of GERD should be included in the management plans for all patients undergoing treatment for laryngotracheal trauma in the acute or late stages. Management should minimally include optimizing antireflux medications and lifestyle modification. In patients whose symptoms cannot be medically controlled, fundoplication may significantly benefit airway recovery.[24]

Physical Examination

With a cooperative patient, nearly all aspects of an airway and voice examination can take place in the office. In addition to carefully listening to the voice and breathing patterns and requiring the patient to simulate the extremes of their breathing, auscultation of the neck is useful. The key examination, though, is endoscopy. Flexible endoscopy should be done first to allow evaluation of palatal lift in the nasopharynx, symmetry and strength of the pharyngeal squeeze,[25] and gross laryngeal movement at the level of the arytenoid body, false vocal fold, and vocal process. Using repetitive tasks is very useful.[26] If the vocal processes are obscured by arytenoid hooding, it may be an indication of pathology.[27] The addition of 2 mL of 2% lidocaine to the tracheal lumen in a transtracheal technique takes only a few seconds, requires no special instruments, and is very well tolerated. It will cause the patient to cough, spraying the lidocaine on the arytenoids and endolarynx, and is the quickest, simplest, and best-tolerated technique for achieving laryngeal anesthesia.

Alternative methods include use of a curved laryngeal cannula transorally, a fiberscope with port to deliver lidocaine transnasally, or inhaled nebulized lidocaine. Nebulized lidocaine is particularly useful in pediatric patients, but the dose of lidocaine given must be tracked because pulmonary absorption is excellent with this technique. After a few minutes, the larynx and trachea will be numb enough to allow awake bronchoscopy. This will allow visualization of the posterior glottis underneath the arytenoid hooding as well as evaluation of the subglottis and trachea. Do not force the endoscope through sections that are narrow in the outpatient setting, because it could induce life-threatening edema of that section later in the day.

For dysphonia, close inspection of the vocal folds is essential and may require the anesthesia technique described above. It is critical to use stroboscopy if it is available. Unless distal chip digital endoscopes are available, every effort should be made to use a rigid 70° or 90° laryngeal telescope.[28] Sataloff et al[29] and Woo et al[30] have written extensively on the evaluation of the larynx with stroboscopic laryngoscopy.

The only difficult aspect of the exam in the awake patient is palpation to determine the mobility of the cricoarytenoid joint. This palpation can certainly be accomplished in the awake patient,[31] but it may more easily be done under general anesthesia, where the controlled environment makes it easier to distinguish vocal process mobility from arytenoid body mobility.

Tests

Pulmonary Testing

The single most useful test for determining if there is a lesion constricting the large airways is a pulmonary function test (Figure 40-1). It documents the volume–velocity curve and can help to localize any flow limitation. Fixed obstructions, such as narrowing of the cricoid or dense scarring of the trachea, will flatten the curve of both the inspiratory and expiratory phases (see Figure 40-1b). Variable obstruction occurs when the airway can still change shape. For a lesion of the supraglottis or glottis, and often in the extrathoracic trachea, the airway narrows during inspiration but expands on exhalation (see Figure 40-

Figure 40-1. Indices of upper airway obstruction (UAO).

(**a**) No airway obstruction.

(**b**) Fixed UAO (usually a fixed narrowing such as tracheal stenosis):
FEV_1 (mL) / PEFR (L / min) ≥ 8 (Empey index; normal < 10)
- FEF50 / FIF50 = 1

(**c**) Variable intrathoracic UAO (tracheomalacia, bronchogenic cysts, tracheal lesions)
- FEF50 / FIF50 ≤ 0.3

(**d**) Variable extrathoracic UAO (pharyngeal / laryngeal obstruction / vocal fold paralysis)
- FEF50 / FIF50 > 1

FEV_1: forced expiratory volume in 1 second
PEFR: peak expiratory flow rate
FEF50 / FIF50: ratio of maximum expiratory to inspiratory flow at 50% of forced vital capacity
UAO: upper airway obstruction

Data sources: (1) Nouraei SA, Nouraei SM, Upile T, Howard DJ, Sandhu GS. A proposed system for documenting the functional outcome of adult laryngotracheal stenosis. *Clin Otolaryngol.* 2007;32:407–409. (2) Garcia-Pachon E, Casan P, Sanchis J. Indices of upper airway obstruction in patients with simultaneous chronic airflow limitation. *Respiration*. 1994;61:121–125. (3) France JE, Thomas MJ. Clinical use of the Empey index in the emergency department. *Emerg Med J*. 2004;21:642–643. (4) Empey DW. Assessment of upper airways obstruction. *Br Med J*. 1972;3:503–505.

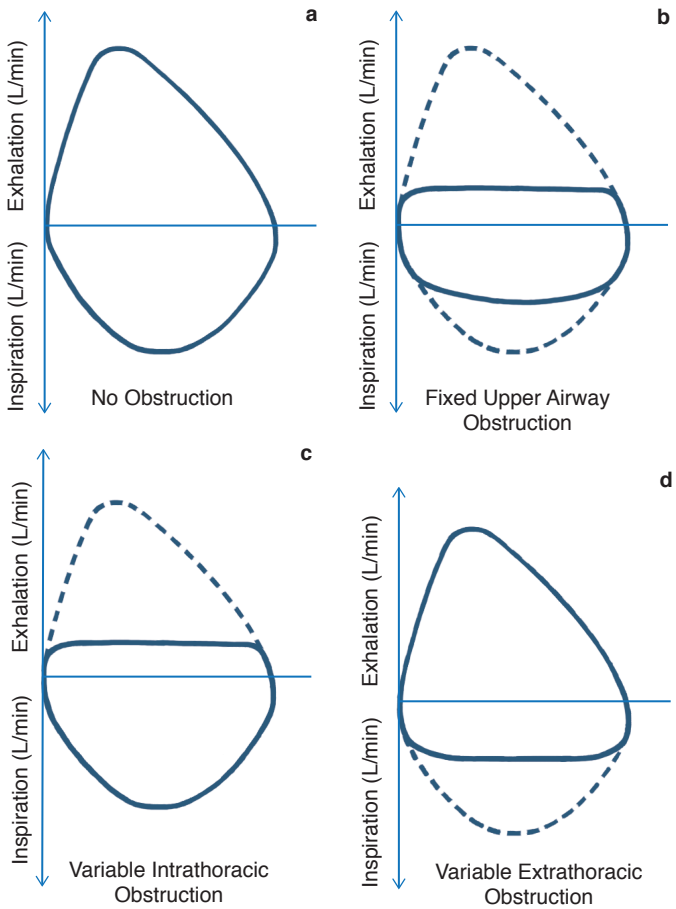

1d). The inspiratory curve is therefore flattened while the expiratory curve is more normal. For intrathoracic tracheomalacia, the opposite is true. Intrathoracic pressures push on the wall and collapse it during exhalation, but negative pressures open it. The expiratory phase is flattened (see Figure 40-1c). Recent work by Nouraei et al identified that the expiratory disproportion index—the ratio of forced expiratory volume in 1 second (FEV_1) to peak expiratory flow rate × 100—had a sensitivity of 95.8% and specificity of 94.2% in differentiating between stenosis and nonstenosis cases.[32,33] The expiratory disproportion index is essentially the same as the Empey index (FEV_1/ peak expiratory flow rate), as shown in Figure 40-1.

Imaging

Noncontrasted computed tomography (CT) scanning of the larynx and trachea is the study of choice for evaluating airway obstruction. Spiral scanning allows triplanar reconstruction, which is very helpful for the surgeon in planning interventions.[34] Surgeons should note the level, length, and thickness of the stenotic segment, and use this information in deciding which procedures would be best for individual patients. Cross-sectional imaging may not show thin webs, and bronchoscopy is essential in patients in whom the imaging and clinical picture do not correlate. Sophisticated postprocessing of images can generate virtual bronchoscopy—a three-dimensional reconstruction with a luminal point of view.[35] Additionally, much like image guidance for endoscopic sinus surgery, electromagnetic navigation systems exist for bronchoscopy, allowing a more refined and precise treatment of the area. These systems are more useful for performing transbronchial procedures, especially in conjunction with endobronchial ultrasound.[36]

Electromyography

While not a common skill set among otolaryngologists, electromyography is a very useful investigation to differentiate neuromuscular vocal fold immobility from scar fixation of the cricoarytenoid joint.[27,37–39]

PATHOPHYSIOLOGY

The pathophysiology of penetrating and blunt traumatic injuries was discussed in Chapter 29, Management of Acute Laryngeal Trauma. This chapter will describe the factors causing delayed voice or airway symptoms.

Intubation-Related Injury

For intubation-related injury, primary factors involved in the development of complications are the duration of intubation and the size of endotracheal tube. Contact with the ETT from its tip and cuff through the airway, pharynx, and oral cavity potentially injures delicate mucosa. Mucosal capillary flow is significantly reduced when intraluminal pressure exceeds 25 mm Hg.[40] Continued pressure eventually leads to mucosal ulceration and edema. Interrupted ciliary mucous transport leads to stasis, which promotes infection and perichondritis. The chondritis and cartilaginous necrosis that can follow result in fibrosis and stenosis, but may also diminish the structural support, causing segmental tracheomalacia.

The areas of greatest risk include the posterior larynx, subglottis, and trachea wall where the cuff of the ETT or tracheotomy tube sits. In the posterior glottis, the relatively firm ETT plastic is forced posteriorly both by the narrower anterior glottis and by the spring and leverage of the ETT as it curves from the lips to the trachea. Finally, the cuff of the ETT exerts pressure against the wall of the trachea to seal the circuit. Respiratory therapists and ICU nurses are trained to check cuff pressure manometrically to prevent injury. Sometimes high inspiratory pressures from the ventilator create a leak around the ETT cuff, which will prompt some providers to add air (and increased pressure) to the cuff. Furthermore, high inspiratory pressures will deform the cuff, pushing all of the air in the cuff to the proximal end. This decreases the surface area of mucosa exposed to the cuff and increases the pressure from the cuff in that area. To prevent this phenomenon, foam cuffs are recommended in patients with high ventilatory pressures.[41]

Many other local tissue factors play a role in injury, as do poor blood supply, immune response, and nutrition. Management of these issues can prevent complications (Exhibit 40-2).

EXHIBIT 40-2

SYSTEMIC FACTORS INVOLVED IN INTUBATION-RELATED LARYNGOTRACHEAL INJURY

- Chronic illness (eg, diabetes, obesity, chronic steroid use)
- Immunosuppression
- Anemia
- Neutropenia
- Dehydration
- Hypoxemia
- Poor perfusion
- Anemia
- Radiotherapy
- Gastric acid reflux

Musculomembranous Vocal Fold Injuries

Anything that disrupts or removes the superficial lamina propria of the vocal folds can cause a change in the voice. The term *sulcus vocalis* refers to a scar on the musculomembranous vocal fold wherein the superficial lamina propria is absent and the epithelium is adherent to the vocal ligament.[42] The scar interrupts the dissipation of energy across the surface of the vocal fold, disturbing vibration. Phonatory tissue stresses around the injured area can induce an inflammatory reaction in the extracellular matrix,[43] which may lead to enlargement of the scar.[44] This is why many phonosurgeons require voice rest after vibratory margin surgery. Late scar contraction can lead to bowing of the musculomembranous vocal fold, which, even when the quality of the voice is fairly normal, can lead to effortful voicing and vocal fatigue.

EXHIBIT 40-3

INJURIES AFFECTING ARYTENOID POSITION

- Unilateral recurrent laryngeal nerve injury (causing either paralysis or weakness)
- Muscular injury
- Vocal process fracture
- Cricoarytenoid joint hemarthrosis
- Arytenoid subluxation/dislocation or fracture
- Scar/contracture

Injuries Affecting Arytenoid Position

In the highly balanced neuromuscular organ that is the larynx, any number of problems can affect arytenoid position (Exhibit 40-3). Scarring that pulls excessively on the arytenoid in any direction will cause asymmetry of vocal process position, changing the aerodynamics and effort of the voice. Careful attention to arytenoid position on awake flexible examination is critical to determining which corrective operations may be necessary.

SITE-SPECIFIC PROBLEMS AND THEIR MANAGEMENT

An exhaustive discussion of each of the possible injuries is beyond this scope of this text. What follows are brief discussions of common late sequelae of laryngotracheal injury and their management. Selected pathologies are illustrated by cases.

Supraglottic Stenosis

Supraglottic stenosis as a result of trauma is very rare,[45] but burn and caustic exposures can lead to significant scarring. Stevens, Chang, and Simpson reported all of their institution's cases (eight) of supraglottic stenosis in their robust tertiary care practice. None were due to trauma (five were from radiation and three from autoimmune disease).[46] Supraglottic stenosis is more frequently iatrogenic and is a well-documented complication of supraglottoplasty and treatment of papilloma.[47] Supraglottic collapse (not necessarily stenosis) may also follow other types of airway surgery, and should be considered in patients who are not substantially improved after other airway enlargement procedures.[48,49] Penetrating trauma can mimic these iatrogenic injuries. Treatment is often dilational. However, a z-plasty may be useful, though challenging to perform endoscopically. Supraglottic laryngectomy has also been successful.[50]

Posterior Glottic Stenosis

Injury to the posterior larynx is most often from prolonged intubation (see Case 40-1). In 1983, Whited demonstrated a 6% incidence of posterior glottic stenosis (PGS) in a prospective study of 200 intubated patients. Many of these patients presented weeks or months after discharge.[5,15] Reflux or infection overlapping an injury may lead to granulation tissue from healing decubiti on the arytenoids, which can fuse, leading to a spectrum of scarring in the posterior glottis.[15] Bogdasarian classified PGS into four categories based on the thickness and location of the scar.[51] In type I, there are interarytenoid adhesions between the vocal processes of the arytenoids but normal mucosa in the posterior commissure. Type II and III PGS are progressively worse, but mobility is maintained in one or both cricoarytenoid joints. Type IV, the worst type of PGS, includes bilateral cricoarytenoid joint fixation.

Management requires that bilateral vocal fold paralysis be ruled out, which may be difficult to do by visual examination alone.[27] Once vocal fold paralysis is ruled out, the scar must be divided. More advanced (types III and IV) lesions require fresh tissue to be brought into the area. Free grafts (buccal or nasal septal, fascia, or skin) or advancement grafts from the postcricoid area or epiglottis can be done in open operations or endoscopically. Posterior cricoid split and cartilage grafting may be useful, particularly in children, and can also be accomplished from an external or an endoscopic approach. The endoscopic procedures are technically very demanding and require advanced laryngologic skills. Although split thickness skin grafts may prevent PGS formation in acute trauma, they are not as useful when operative management is required later.

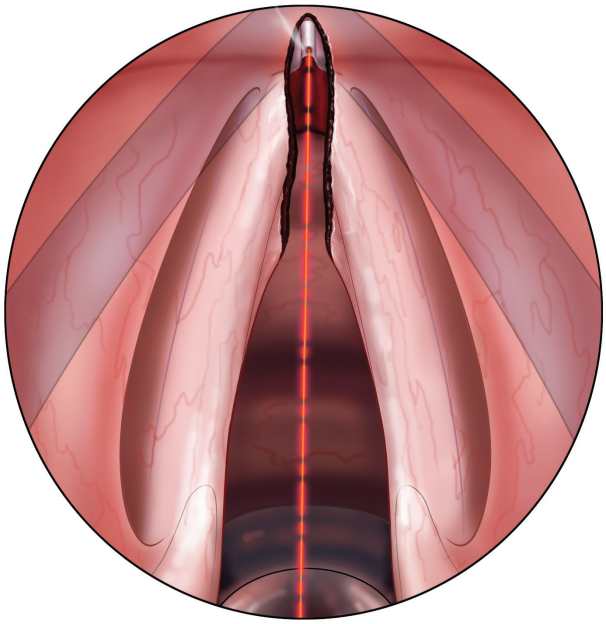

Figure 40-2. "Key hole" technique using a carbon dioxide laser to continue the division of a glottic web well into the natural anterior commissure. The intent is to "overdo" the correction in anticipation of scar formation.
Drawing reproduced with permission from: Rosen C, Simpson B. *Operative Techniques in Laryngology*. Berlin, Heidelberg: Springer Verlag, 2008. With kind permission of Springer.

Glottic Webs

Anterior glottic webs do not always need to be divided. If the voice and exercise tolerance are acceptable, anterior webs may remain. Webs shorten the vibratory length of the musculomembranous vocal folds and thus increase the fundamental frequency of vibration. If the vocal folds posterior to the web

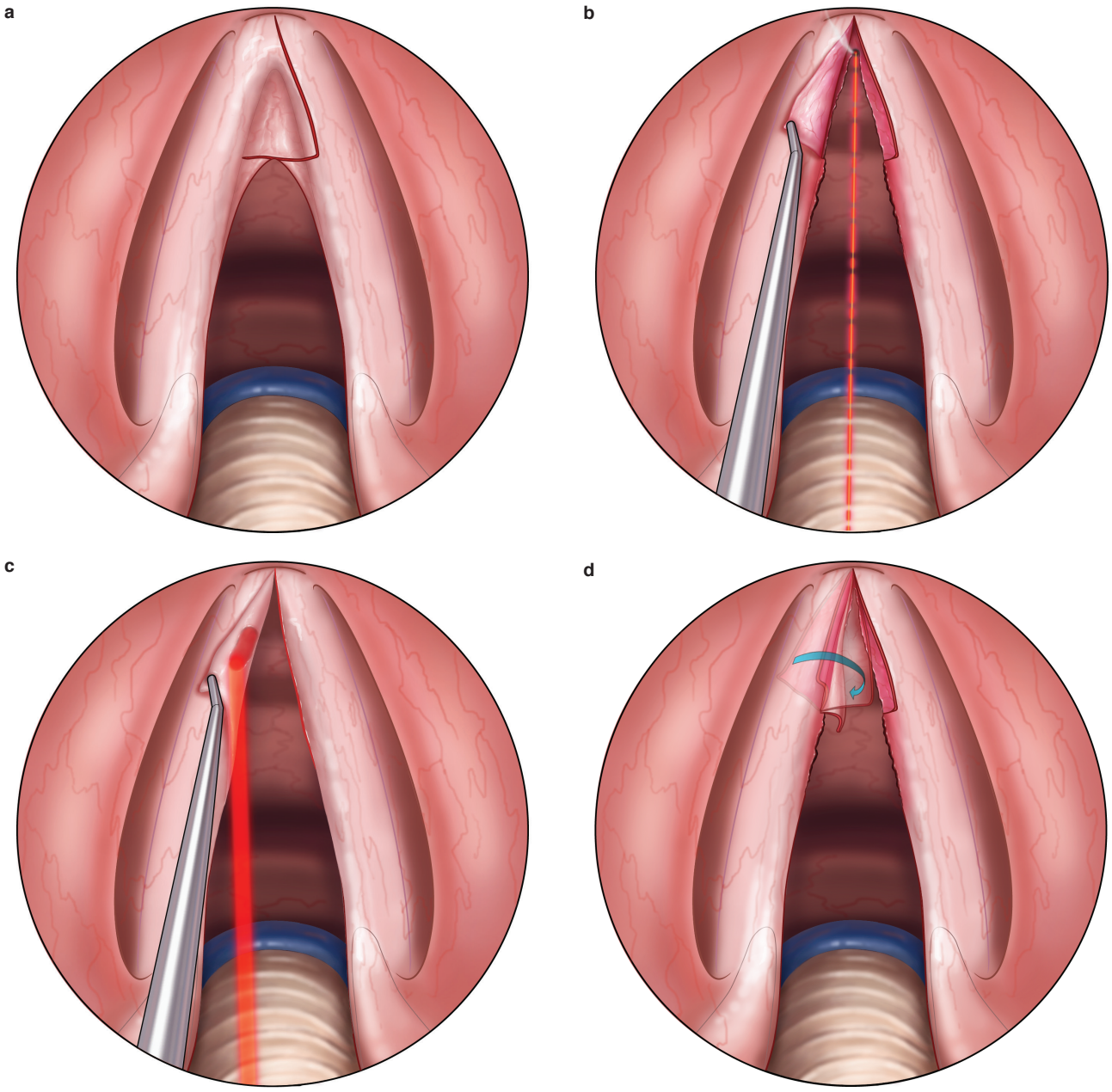

Figure 40-3. Single-stage repair of an anterior glottic web as proposed by Schweinfurth. (**a**) Flap design. (**b**) The incision carries full thickness through the web, leaving a raw surface on the right vocal fold. (**c**) The under surface of the flap is de-epithelialized with a defocused laser beam, including the recipient area on the left vocal fold. Care must be taken to preserve the remaining flap. (**d**) The flap is then placed over the left vocal fold and secured with a suture.
Data source: Schweinfurth J. Single-stage, stentless endoscopic repair of anterior glottic webs. *Laryngoscope*. 2002;112:933–935. Drawings reproduced with permission from: Rosen C, Simpson B. *Operative Techniques in Laryngology.* Berlin, Heidelberg: Springer Verlag, 2008. With kind permission of Springer.

are normal, then the voice will be of good quality. Because the posterior glottis is primarily responsible for respiration, breathing is not generally impaired until the web approaches the vocal processes or limits their lateral excursion. For patients who desire either an improvement in phonation or breathing, the web can be divided. Thin webs can simply be divided, commonly with cold steel or with a laser. Using a carbon dioxide laser on a micromanipulator utilizing the smallest spot size and low power is recommended. Many authors advocate using the laser to divide the soft tissue all the way into the thyroid cartilage, making the resulting defect resemble a "key hole." Rosen and Simpson use a fine spot size to make a 1-mm trough (Figure 40-2).[52] Thicker webs do not do well with simple division because of the amount of scarring that will be present on the vibratory surface. For thick webs, a curvilinear flap is made by dividing the web asymmetrically, de-epithelializing the undersurface of the web by defocusing the laser, and then laying the flap over the vocal fold (coapting the raw surfaces) and securing it (Figure 40-3).[53,54]

Most surgeons place a keel to separate the anterior commissure during healing. Silastic, silicone, and prefabricated keels, such as the Montgomery keel, have been used. The senior author (RLE) advocates for the use of a Gore-Tex (Gore and Associates, Elkton, MD) keel secured with a heavy Prolene suture (Ethicon Inc, West Somerville, NJ) using translaryngeal sutures (see Chapter 29, Management of Acute Laryngeal Trauma). The soft Gore-Tex effectively separates the tissues, but does not damage the vocal folds. The keel is left in place for 7 to 10 days (Figure 40-4).

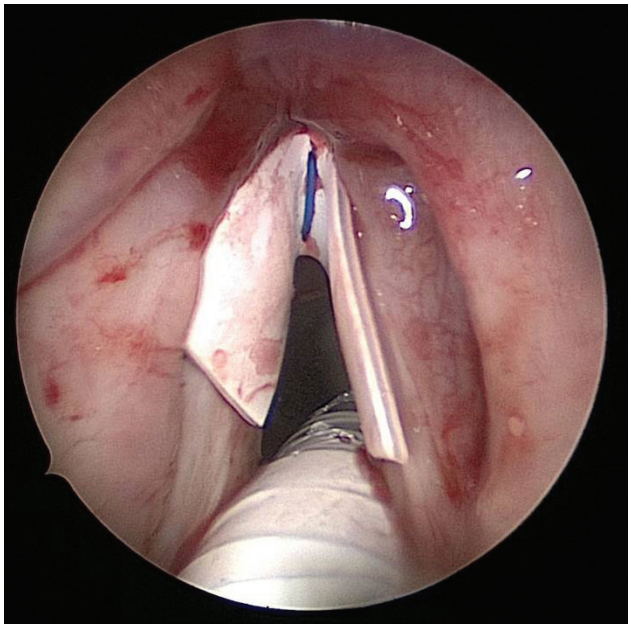

Figure 40-4. Gore-Tex (Gore and Associates, Elkton, MD) keel held in place with heavy PROLENE (Ethicon Inc, West Somerville, NJ) suture.

Subglottic and Tracheal Stenosis

Grading Systems and Choice of Management Procedures

Several grading scales have been devised that can be used for documenting condition severity. They are also useful for planning treatment and the informed consent process. The following three scales are preferred. The Cotton grading of laryngeal stenosis is based on the percentage of lumen obstructed (Table 40-1).[8] The McCaffrey grading system[55] (Table 40-2, Figure 40-5) relies more on subsites (trachea, subglottis, glottis) and length of stenosis. This system has been found to better predict eventual extubation in adult patients following stenosis repair.[56] Functional assessments, such as the Adult Airway-Dyspnea-Voice-Swallowing System (Exhibit 40-4) developed by Sandhu's group in the United Kingdom, are used to help surgeons and patients understand the benefits and limitations of different surgical procedures. Specifically, they explain the benefits of more aggressive surgery when limited surgical intervention has not improved the patient's perceived functional capacity even though there may be a large improvement in size of the stenosis.[57]

Management of tracheal stenosis includes a variety of procedures that can be separated into endoscopic or external modalities. Endoscopic methods include balloon dilation and laser excision of stenotic areas. Open surgical methods include expansion and resection surgery. Each patient will need evaluation for the particular modality utilized; open techniques are associated with higher morbidity and mortality, but endoscopic techniques may be futile if inappropriately

TABLE 40-1

COTTON SCALE OF SUBGLOTTIC AND TRACHEAL STENOSIS

Grade	Extant of Lumen Obstructed
I	Less than 70%
II	70% to 90%
III	More than 90%; identifiable lumen is present (no matter how narrow)
IV	Complete obstruction; no lumen

TABLE 40-2

MCCAFFREY STENOSIS GRADING SYSTEM

Stage	Extent of Stenosis
I	Confined to subglottis or trachea, <1 cm
II	Isolated to subglottis/cricoid area, >1 cm
III	Subglottis and tracheal
IV	Lesions involve the glottis

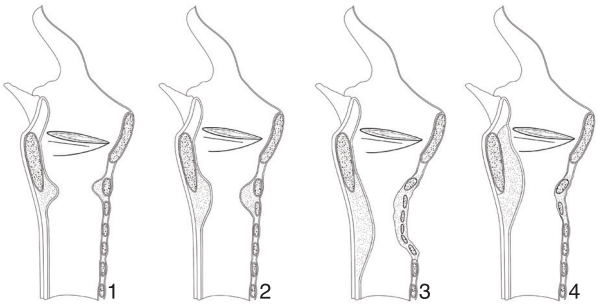

Figure 40-5. Stages 1 through 4 of McCaffrey stenosis scale. *Note*: laryngeal involvement (stage 4) with vocal fold fixation significantly worsens probability of decannulation.
Data source: McCaffrey TV. Classification of laryngotracheal stenosis. *Laryngoscope*. 1992;102:1335–1340.

used. In general, more severe cases of tracheal stenosis require open techniques. This is particularly true if the cartilaginous framework is affected, rendering endoscopic techniques less effective. Based on the Cotton grading system, an endoscopic technique may be useful for grade I and some grade II patients. More specifically, endoscopic procedures work well when the stenosed segment is thin and short. Expansion laryngotracheal surgery, such as anterior or posterior cartilage graft placement, is very successful for grades II, III, and some grade IV stenosis. Partial cricotracheal resection is successful in some grade III and IV stenosis when there is a clear margin between the stenosis and the vocal cords.[8] Stenotic recurrence must be monitored after corrective procedures. Patients with worsening stenosis despite endoscopic management warrant intervention with an open procedure.

Endoscopic Procedures

Endoscopic balloon dilation is a very well tolerated procedure with frequently satisfying results. Unfortunately, the long-term success rates of balloon dilation in tight lesions (Cotton stages 3 and 4) are poor and maintenance procedures are required.[58] The literature supports repeat dilation of stenosis following recurrence,[59,60] with nearly half of patients who fail initial dilation experiencing success with a second dilation.[59,60] The second author (NSH) prefers to perform a series of three dilations with severe stenosis, with 6 weeks between the first two and 8 weeks between the second and third dilation to maximize benefit. Balloon dilation is also a good temporary measure to treat a patient until an open procedure may be performed.

The carbon dioxide laser has significantly improved the ability to shape the intraluminal trachea, which improves the chance of success with dilations. Some surgeons use the laser to create radial incisions prior to dilation. One author (NSH) prefers to laser after dilation because the act of dilation often presents a quadrant of tissue that is ripe for removal to expand the airway. Laser and balloon treatments are best for thin and non-circumferential stenosis with adequate cartilaginous support.

Intra-scar steroids (dexamethasone 10 mg/mL) or topical application of antiproliferative agents (0.5–1 mg/mL mitomycin C, an antineoplastic antibiotic with effects on fibroblasts) have some potential for reducing scar formation after these procedures, but the effects are very limited.

Tracheal stents have been proposed for use in patients who fail other endoscopic techniques. A stent is frequently considered in patients who are poor candidates for open procedures, which generally have better success rates. Alternative options for patients who either cannot have open surgery or wish to avoid reconstructive surgery include a tracheotomy at or below the level of the stenosis to bypass the stenosis, or use of a T-tube to perform an intraluminal stent of the airway.

Open Single-Stage Procedures

Tracheal resection with anastomosis. In a study by Herrington et al,[59] the authors performed 384 procedures on 127 patients, with 298 airway dilations. Ninety-one of the 127 patients underwent primary dilation and 36 patients had primary open surgery. Sixteen of 80 patients (11 were lost to follow-up) with primary dilation had an adequate airway after the first procedure (20%). Only 36% were eventually cured with dilation alone, and 37 patients (46%) went on to open tracheal resection. Of the 36 patients who had primary open procedures, 20 were cured after the procedure (55%). Thus, in this study, open tracheal resection was more likely to cure the patient on the first attempt than endoscopic techniques. Of course, the endoscopic option is much less morbid, and may be a better option for frail patients.

EXHIBIT 40-4

THE ADULT AIRWAY-DYSPNEA-VOICE-SWALLOWING SYSTEM

Airway Status (A)
1. No airway prosthesis.
2. Intraluminal airway prosthesis (stent).
3. Airway stoma present in the neck (tracheotomy, T-tube, or tubeless tracheostomy); patient voices.
4. Airway stoma present in the neck; patient does not voice.
5. Death as a result of a complication of airway disease.

The following three components of the scale are patient-administered and by default relate to symptoms experienced in the week prior to the application of the test. They could be used to encompass longer time spans, but this needs to be explicitly specified as part of documenting the results.

Dyspnea (D)
1. I get short of breath only on strenuous exercise.
2. I get short of breath when hurrying on the level or up a slight hill.
3. I walk slower than people of the same age on the level because of breathlessness, or have to stop for breath when walking at my own pace on the level.
4. I stop for breath after walking 100 yards or after a few minutes on the level.
5. I am too breathless to leave the house.

Voice (V)
1. I have had no problems with my voice.
2. I have had some problems with my voice. For example:
   - The sound of my voice may vary throughout the day.
   - I have had some difficulty being heard/understood in loud environments.
3. I have quite a rough voice. I find making voice effortful and have significant difficulties being heard/understood in loud environments.
4. I can only produce a weak voice/whisper despite my best efforts, and have difficulty being heard/understood in normal conversation or on the telephone.
5. I have no voice.

Swallowing (S)
1. I have been able to eat and drink normally.
2. I have been able to eat a normal diet but with some difficulty. For example:
   - I have occasionally had to cough to clear my throat.
   - I find some foods more difficult than others to swallow.
   - It takes me longer to finish a meal than it does people around me.
   - I tend sometimes to cough when I drink liquids quickly.
3. I have had significant swallowing difficulties. For example:
   - I have tended to cough to clear my throat, or do a double swallow during most meals.
   - I tend to eat soft or pureed foods that are easier to swallow.
   - It takes me much longer to finish a meal than most people.
   - Drinking fluids frequently makes me cough.
4. My swallowing is a serious problem/is seriously abnormal. For example:
   - My diet consists almost entirely of semi-liquid/liquidized foods.
   - I need to take a significant amount of the fluids I drink as thickened fluids.
   - I take regular dietary supplements—or—I receive a proportion of my diet through a stomach tube (PEG).
5. I am unable to swallow. I take all of my nutrition through a stomach tube (PEG).

Reproduced with permission from: Nouraei SA, Sandhu GS. Outcome of endoscopic resection tracheoplasty for treating lambdoid tracheal stomal stenosis. *Laryngoscope*. 2013;123:1735–1741.

The open procedure is performed with a low collar incision with elevation of the subplatysmal flaps to the level of the hyoid and the manubrium. The thyroid gland is divided in the midline and the anterior aspect of the trachea is identified. Blunt dissection is performed from the cricoid distally to identify the stenosis. The stenotic section will be easily observed due to its external effect upon the trachea. However, identification may be challenging, and a needle placed into the airway can be visualized with a bronchoscope to confirm the level of the stenosis. Circumferential dissection around the stenotic segment will allow its resection. Hugging the tracheal wall will prevent recurrent laryngeal nerve injury. See also Case 40-2.

Laccourreye et al noted that tracheal elasticity alone allows for 2 cm of resection with no other release maneuvers.[61] For segments longer than 2 cm, excessive anastomotic tension may result unless releasing maneuvers are performed. Avoiding lateral dissection above and below the stenotic area preserves the blood supply to the remaining trachea and promotes wound healing. Together, the anterior and posterior blunt dissection will easily give the surgeon 3.5 cm of resection without requiring more destructive release maneuvers. (*Note*: there are approximately two tracheal rings per centimeter of trachea.) However, additional release maneuvers may be required.[61,62] Options include:

- anterior mediastinal dissection,
- suprahyoid laryngeal release (transecting the muscles and fascia between the hyoid and the mentum),
- infra-hyoid laryngeal release (transecting the muscles and fascia between the hyoid and thyroid cartilage), and
- cardiothoracic procedures (release of pulmonary ligament and reanastamosis of left main stem to bronchus intermedius, used for segments longer than 6 cm).

An additional 1 to 2 cm can be obtained with each of these maneuvers, but patients will commonly suffer dysphagia with the supra-laryngeal releases. Cardiothoracic surgery assistance may be required if over 6 cm of trachea is to be removed to perform thoracic release maneuvers.

Anastomosis is performed after returning the head to a neutral position (removing the shoulder roll) with absorbable sutures (3-0 VICRYL [Ethicon Inc, West Somerville, NJ]), with the posterior suture line performed first. Once the posterior half of the sutures are complete, an orotracheal tube is advanced distal to the site to assume the airway duties so that the remainder of the closure can be performed. Two additional sutures may also be placed to reduce stress on the airway: a stitch between the internal aspect of the manubrium to the anterior trachea, and a double looped secondary stitch to provide a secondary tension relief. Barbed suture may also be helpful (Paul Castellanos, MD, University of Alabama, Birmingham, personal communication, 2013). With these sutures in place and a cervical neck collar, a Grillo stitch (1-0 PROLENE [Ethicon] from the submentum to the chest) is not routinely used.[61]

Cricotracheal resection. Cricotracheal resection is an expanded use of the tracheal resection technique in which a portion of the stenosed cricoid is also removed. The intraluminal scar at the level of cricoid is typically removed submucosally rather than removing the entirety of the cricoid. The trachea is advanced superiorly into the larynx. Figure 40-6 graphically demonstrates the technique. It is common to consider use of a tracheotomy or T-tube in patients after this procedure.

Multistage Laryngotracheoplasty

The most extensive wartime tracheal and laryngeal injures have always been a challenge for the airway surgeon. Laryngotracheal reconstruction is most difficult when the necessary framework support is lacking, especially after significant penetrating injury. The

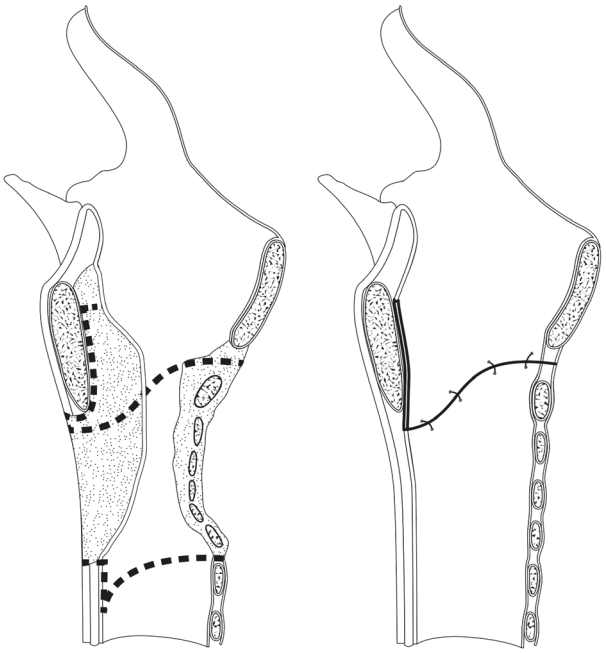

Figure 40-6. Cricotracheal resection.
Data source: Laccourreye O, Brasnu D, Seckin S, Hans S, Biacabe B, Laccourreye H. Cricotracheal anastomosis for assisted ventilation-induced stenosis. *Arch Otolaryngol Head Neck Surg*. 1997;123:1074–1077.

multistage laryngotracheoplasty (MSLTP) is ideal for long segment posterior and high tracheal stenosis, and for glottic, supraglottic, and multilevel stenosis (see Case 40-3). Patient selection is important because the outcome may be limited in those who have had neck radiation or who form hypertrophic scars.

Attempts to reconstruct the larynx in this fashion date to 1896, when Fritz Koenig realized that negative inspiratory pressure caused collapse of the laryngotracheal segment. He attempted to use rib tissue placed into a cutaneous pocket to later be swung over the flap to cover the defect. In 1927, Fred Fairchild described an adaptation of this technique: he performed a three-stage procedure in which a skin flap was used to line the defect posteriorly, a contralateral flap was positioned to meet this flap, and in the final stage a skin tube was created to form the high trachea. This repair eventually failed, but the technique was later used successfully as a Wookey flap.[63] In 1951 this technique was modified by Max Som, who used a split thickness skin graft to reconstruct the airway mucosa and implanted a rigid mesh material below the skin that would become the anterior airway. Reconstruction of the airway took 4 ½ months, and the patient had an "adequate airway" at 6 months.[64] Additional modifications were made to this technique by Serrano, Montgomery, Grillo, Bryce and Lawson, Krizek and Kirchner, Friedman, and Lawson between 1959 and 1977. Biller et al reported on a 30-patient case series using the technique in 1986,[65] and Isshiki et al reported on a nearly identical procedure using a buccal mucosal graft in 1991.[66]

Current MSLTP continues to utilize three staged procedures (Figure 40-7):

1. A tracheotomy is performed and the larynx and trachea are opened via a laryngofissure. The remaining cartilaginous structure is secured to the ipsilateral external skin (in an open book configuration). The scar is removed and abnormal mucosa is replaced with grafts (buccal, septal, or turbinate), which are supported by a bolster (Coe-Soft [GC America, Alsip, IL] dental material). After 1 week, the bolster is removed and healing is allowed to continue for several weeks.
2. When the mucosa has matured, rigid Marlex (Chevron Phillips Chemical Co, The Woodlands, TX) mesh is placed under the skin adjacent to the defect.
3. The skin is rotated inward to become the internal anterior laryngotracheal wall and wide undermining is performed to close the neck over a T-tube.

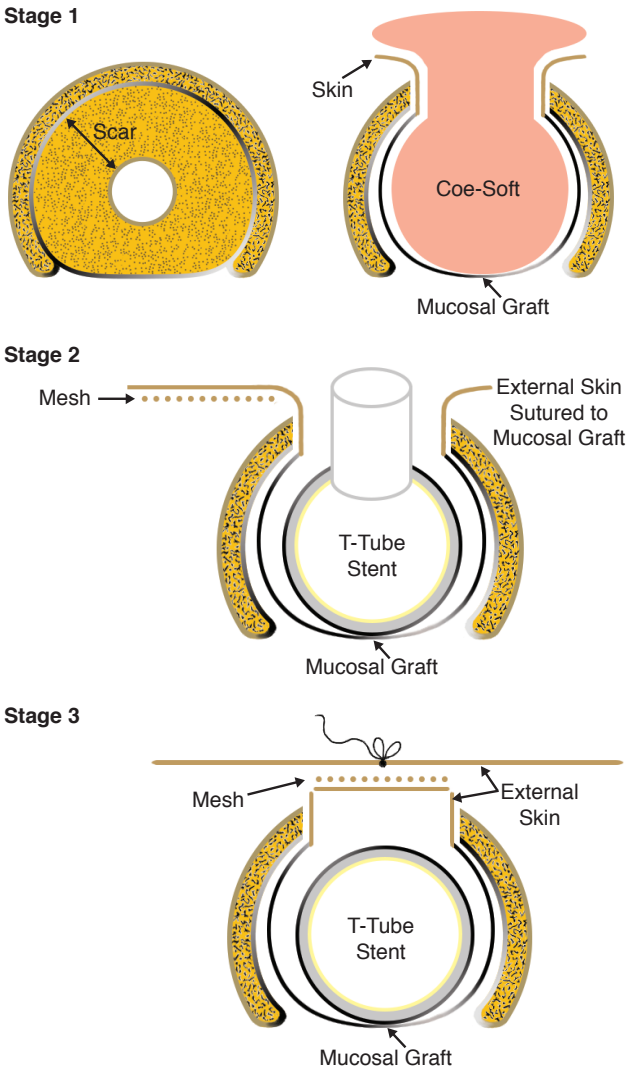

Figure 40-7. Multistage laryngotracheoplasty. **Stage 1:** Vertical incision through and removal of the scar, preserving the framework of the trachea or larynx. Application of mucosal graft and bolster with Coe-Soft (GC America, Alsip, IL). External skin sutured to mucosal grafts and inner lining of airway. **Stage 2:** Removal of Coe-Soft bolster and placement of T-tube. Insertion of mesh or use of other support (ie, rib graft) dependent upon native airway structure. Externalizing sutures may also be used to stabilize airway. **Stage 3:** Inversion of the external skin to replace the anterior tracheal wall and provide laryngeal support. T-tube is removed when airway is demonstrated to be stable. (3 weeks to 3 months after stage 3).

Alternative maneuvers to perform steps 2 and 3 include using a muscle flap or cartilage-muscle flap (an autologous rib placed within a sternocleidomastoid flap).

Factors associated with failure of this technique include a poor blood supply to laryngeal tissues second-

ary to prior open attempts at repair, complete loss of all cartilage support, infection, chronic posterior scar, glottic involvement, and a vertical scar length over 1 cm (Dr Gerald Berke, Chairman of Otolaryngology at University of California–Los Angeles, personal communication, 2010).

OTHER CAUSES OF AIRWAY NARROWING

Tracheotomy-Related Granulation Tissue

Granulation tissue often forms where the distal end of the tracheotomy tube rubs on the tracheal wall and on the anterior edges of the trachea within the stoma. With fenestrated tracheotomy tubes, the irritation may be on the membranous trachea. The presence of the tracheotomy tube prevents granulation tissue from enlarging just inferior to the stoma, but suprastomal growth can become quite large, obstructing the tracheal lumen. Aggressive therapy to mitigate granulation tissue formation through treating GERD and bacterial infections is crucial to the management of these patients. Yellon et al reviewed the literature in an article on the subject, referencing several canine and rabbit studies that have shown tracheotomy-associated peristomal granulation tissue following bacterial infection, with subsequent decrease in stenosis with antibiotic use.[67]

Various methods can be used to manage suprastomal granulation formation. External exploration of the tracheostoma prior to decannulation allows for overt observation and removal of possibly obstructing tissue.[67] The use of rigid bronchoscopic guidance for removing granulation tissue through the stoma prior to decannulation has been described by several authors.[47,68–70] For this technique, optical forceps, electrocautery, coblation, or a microdebrider may be used. In the presence of total or near-total obstructing suprastomal granulation tissue, if endoscopic removal is unsuccessful, an open tracheoplasty approach should be used (with the tracheotomy tube left in place to secure the airway).[67] Prescott[71] concluded that formation of a formal tracheostoma with the skin sutured directly to the opening in the tracheal cartilage may decrease formation of suprastomal granulation tissue by decreasing the rate of bacterial tracheitis.

Lambdoid Tracheal Stenosis

Lambdoid deformity of the trachea is a specific variant of posttracheotomy airway stenosis that results from the collapse of tracheal rings split during the procedure or damaged by pressure from the tube. After the tube is removed, stomal wound contracture causes a lambda-shaped (Λ) anatomical deformity and airway compromise.[57] Typically occurring 3 to 4 cm below the vocal folds, this posttracheotomy complication is associated more with surgical tracheotomies than with percutaneous tracheotomies.[72] Percutaneous tracheotomy stenosis is more likely to occur in the subglottis and proximal trachea than that caused by surgical tracheotomies. More commonly, lamboid stenosis is caused by stomal contracture. Less commonly, scarring extends beyond the anterior tracheal wall and involves the trachealis and lateral trachea. When this occurs, endoscopic success is less likely.[57] Additional airway obstructions such as trachealis promontories (anterior bulging of the posterior tracheal wall) are fairly common with lambdoid deformities as well.[20]

Traditionally, primary resection and end-to-end anastomosis have been recommended for treating this condition. More recently, a two-stage endoscopic resection tracheoplasty using a carbon dioxide laser has been utilized and is suggested as a safe and effective treatment for this airway lesion.[20,57] This procedure avoids many of the complications associated with end-to-end reanastomosis, and reserves open resection in the event of endoscopic failure. The proximal tracheal and cricoid lesions noted with percutaneous tracheotomies may require partial resection of the cricoid for lambda deformity in this area.[34]

Tracheomalacia

While typically associated with weak cartilage in pediatric patients, tracheomalacia can be a late complication of prolonged or overly aggressive endotracheal intubation. Diagnosis of tracheomalacia typically depends on a high index of suspicion. For example, difficulty weaning a ventilated patient off positive pressure ventilation or a patient who has had a previous intubation or tracheostomy may present with new and gradually worsening dyspnea. Positional dyspnea is especially concerning.

Seated and supine flexible bronchoscopy can be used to observe the movement of the cartilaginous trachea. Pulmonary function tests can show evidence of variable intrathoracic obstruction.[73] Additionally, airway fluoroscopy may show dynamic tracheal collapse.[74]

Holding the trachea open is the focus of treating symptomatic tracheomalacia. An intraluminal device such as a tracheotomy or T-tube is very effective. While

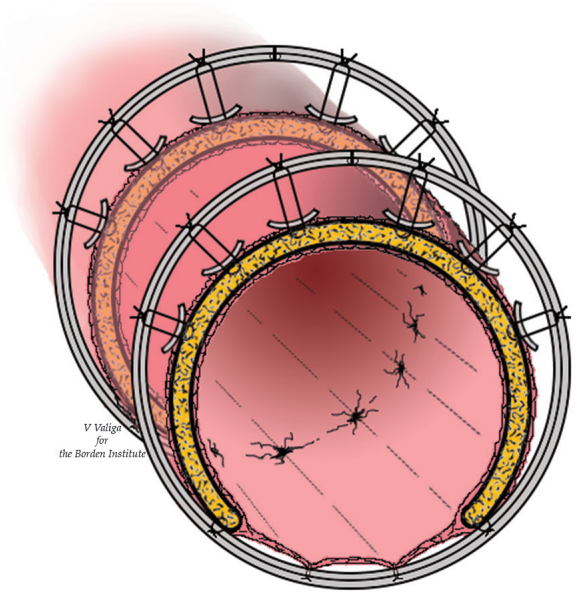

Figure 40-8. Schematic cross-sectional view of tracheal external stabilization with "on-lay" fixation of the flaccid membranous trachea and free suspension of the malacic cartilaginous portions within an oversized polytetrafluoroethylene prosthesis.

expandable metallic stents have been advocated for this purpose,[75] internal stenting with expandable stents can lead to complications such as granulation tissue, stent migration, stent expectoration, halitosis, mucous retention, and mucus plugging.[76,77] Many of these complications can be managed medically; however, additional procedures may be required after stenting.[28]

Extraluminal treatments include suspending the aorta from the sternum to create space anterior to the trachea.[78] Recently, external tracheal stabilization attempts have used tailored silicone tubing or ceramic rings (Figure 40-8).[79,80] These methods allow for increased stabilization of the malacic segment while avoiding insertion of a foreign body inside the airway (as is done with internal stenting).[81]

Suprastomal Collapse

Posttracheotomy suprastomal collapse is very similar to peristomal tracheomalacia in etiology and presentation. Often what distinguishes the two is the prior airway intervention utilized. Tracheomalacia is associated more with prolonged endotracheal intubation, while suprastomal collapse is more closely tied to long-standing tracheostomies. There is no absolute anatomic difference between the two conditions, and in practice their management is similar. In their 2007 review of the topic, Anton-Pacheco et al[82] reported that suprastomal cricotracheal collapse is responsible for 2.4% to 18% of decannulation failures with long-standing tracheostomies, especially in pediatrics. While no studies specifically note varied levels of collapse when comparing surgical and percutaneous tracheotomy, this study found a significantly higher rate of suprastomal collapse (18%) in patients with H-type tracheotomies when compared to vertical midline incision techniques (2%).[82] The H-type tracheotomy creates a narrower tracheal window, causing continuous pressure on the tracheal wall that can lead to increased tissue necrosis and breakdown. Thus, it is important for all otolaryngologists evaluate their own surgical tracheotomy preferences and understand the observed complication rates seen with each type of procedure.

There are several ways to manage suprastomal collapse in a patient. Carbon dioxide or potassium titanyl phosphate laser reshaping can be useful. Management can be as simple as intubating the patient with an endotracheal tube bypassing the stenosed segment, though this is not a good long-term solution. The segment may be suspended with a suture originating on the thyroid notch and traveling over the cricoid arch to the distal edge of the malacic segment. A subcutaneous suture may also be used to pull the anterior tracheal wall forward. Benefits of procedures such as these are their simplicity and avoidance of indwelling luminal devices.

SUMMARY

Although entire textbooks are dedicated to this subject, this chapter is intended to prepare the reader to suspect, discover, and treat patients with late complications of airway injury. A general otolaryngologist will likely refer many of these patients to subspecialty centers, but the detail provided here provides a starting place for deployed surgeons caring for host-nation patients. Working with other specialties is critical, and time spent working with burn surgeons, cardio-thoracic surgeons, pulmonary medicine specialists, and plastic surgeons will enable appropriate and early referral, which is good for both the patients and the surgeons in the long run.

CASE PRESENTATIONS

Case Study 40-1

Presentation

A 23-year-old male US Army soldier with a history of traumatic multilimb amputation while serving in Iraq was emergently intubated and evacuated to Walter Reed Army Medical Center. The patient had multiple surgeries with the orthopedic service. He presented to the ear, nose, and throat department with symptoms of acute dysphonia, breathy voice, and vocal fatigue. Bilateral vocal process granulomas were documented following extubation and closely monitored during his hospitalization and recovery.

Preoperative Workup/Radiology

Early endoscopic examination performed in the clinic revealed granulation tissue overlying the mucosa of the medial surface of the vocal process of the arytenoid (Figure 40-9). Nonsurgical management (inhaled steroids, antibiotics, and antireflux medications) were utilized and monitored via serial video endoscopies. Transformation of the granulation tissue was monitored and voice and airway complaints were recorded (Figures 40-10 and 40-11).

Operative Planning/Timing of Surgery

The patient's early voice changes initially improved but then worsened over the last few weeks of conservative management to include symptoms of dyspnea on exertion, mild dysphagia, and a foreign body sensation in the throat (Figure 40-12). The timing and decision to perform surgery was directly related to the occurrence of these symptoms.

Operation

The rigid interarytenoid band was seen anterior to endotracheal tube following intubation (Figure 40-13). Microscissors were used to cut the bilateral scar band (Figure 40-14). Postoperative reflux management and oral steroids were provided. The patient healed well and was asymptomatic at long-term follow-up.

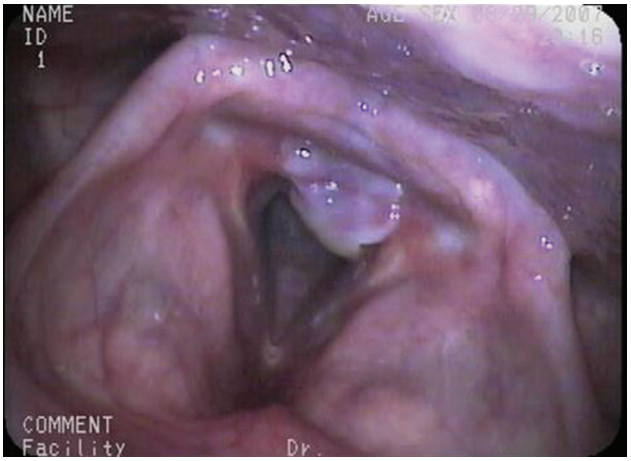

Figure 40-10. Formation of posterior glottic adhesion—fully mobile vocal folds.

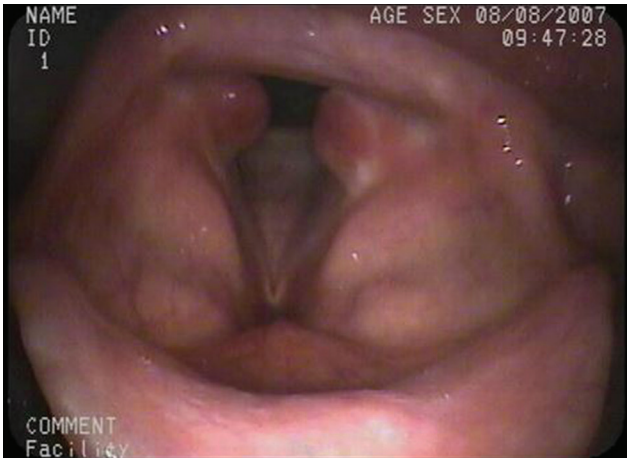

Figure 40-9. Early bilateral granulation tissue.

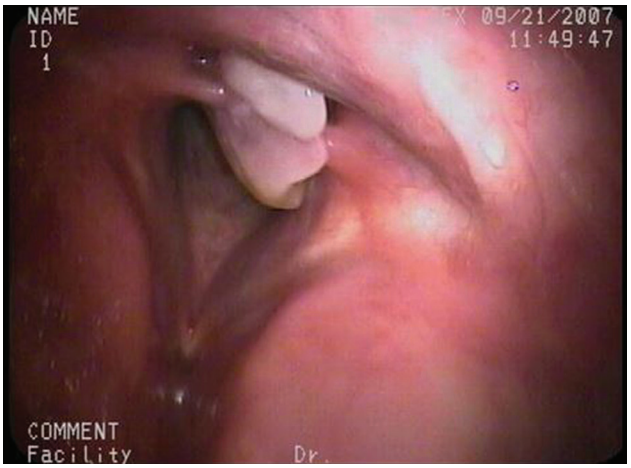

Figure 40-11. Mature posterior glottic granulation tissue.

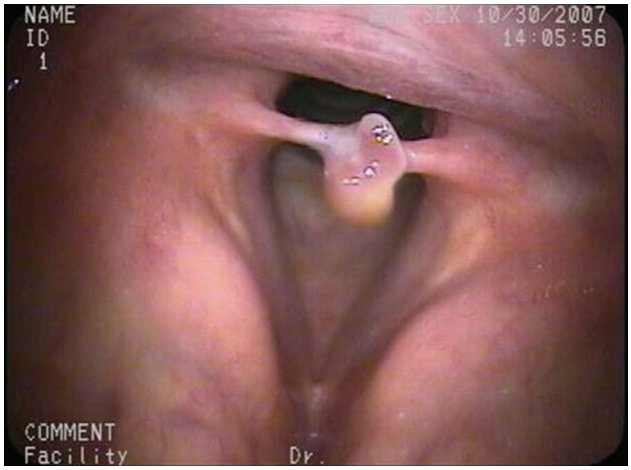

Figure 40-12. Interarytenoid adhesion. Patient notes some restricted airflow.

EXHIBIT 40-5

PROPOSED STAGES OF DEVELOPMENT

1. Intubation injury → ulceration → granulation tissue
2. Bilateral tissue contact → interarytenoid bridge formation
3. Resolution of granulation with persistent adhesion band
4. Maturing and shortening of adhesion band causing bilateral vocal cord immobility

Complications

None.

Lessons Learned

This case demonstrates the sequential formation of an interarytenoid adhesion (Exhibit 40-5). Close monitoring of this individual's symptoms and findings on video endoscopy enabled surgical intervention to be done when the symptoms revealed dysfunction. Late discovery of interarytenoid adhesions may appear to mimic bilateral vocal fold paralysis or a normal exam with arytenoid hooding. A high clinical suspicion is warranted when vocal fold immobility or reduced mobility is discovered.

Case Study 40-2

Presentation

A 27-year-old Special Forces soldier who was intubated and sedated for 14 days following a motor vehicle accident had no difficulty being weaned from

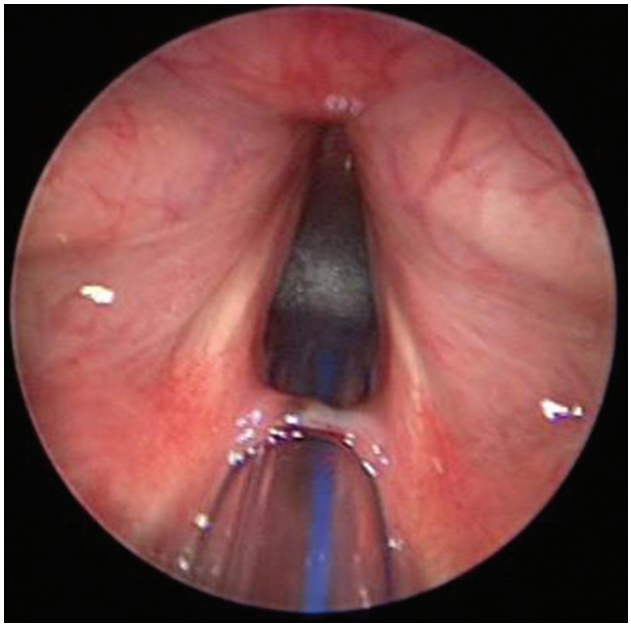

Figure 40-13. Intubation occurs directly behind tough adhesion.

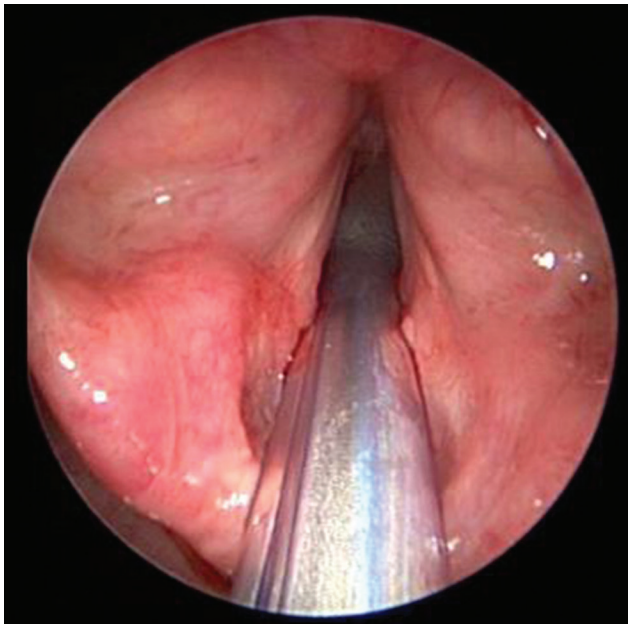

Figure 40-14. Lysis of adhesion with laryngeal micro-scissors. Patient asymptomatic.

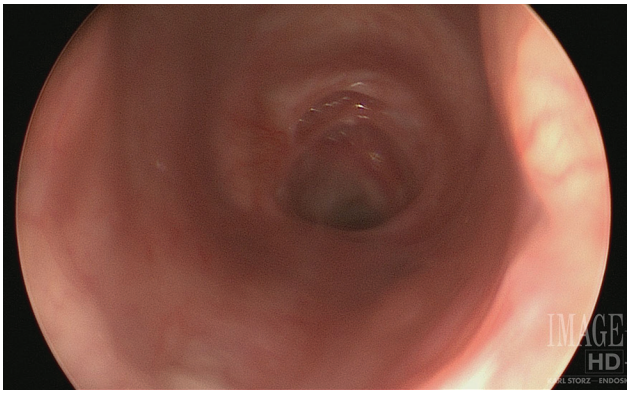

Figure 40-15. Prior to dilation. Patient had been dilated four times prior to this within span of 2 months.

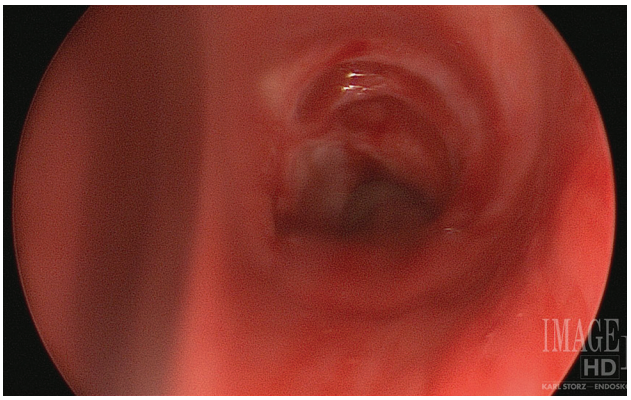

Figure 40-16. After multiple attempts at dilation. Note minimal displacement of tissues.

the ventilator but required additional surgical procedures with intubations described as difficult by the anesthesia team. Airway stenosis was identified and treated initially with dilations four times with minimal benefit (Figure 40-15).

Preoperative Work-up/Radiology

CT imaging showed 2.5-cm stenotic area. Bronchoscopy performed in clinic showed a tight (>50%) stenosis not involving the cricoid.

Operative Planning/Timing of Surgery

The soldier was transferred from a distant medical center to a tertiary care military hospital for airway surgery. With four prior minimally successful dilations performed and findings suggestive of tight stenosis on examination in clinic, it was anticipated that tracheal resection would likely be required.

Operation

Direct laryngoscopy and bronchoscopy under spontaneous ventilation was performed at the beginning of the case to inspect and measure the stenosis. Balloon dilation was repeated to determine its effect, but minimal improvement occurred (Figure 40-16), and open tracheal resection was then performed. A 3.5-cm section of trachea was removed with minimal inferior anterior-posterior release maneuvers required. A Grillo stitch was not placed; instead, the patient was placed in cervical collar for 1 week (Figure 40-17). He was transferred home with follow-up with local otolaryngologist.

At 1 month postoperation, the patient resumed full activities including all Special Forces training. He described no limitations. A bronchoscopy was performed by his pulmonologist at 8 months with excellent exercise tolerance and normal spirometry.

Complications

None.

Lessons Learned

Iatrogenic injury secondary to multiple intubations following trauma is common. Patients who require extensive surgery with repeated planned irrigation (washouts) and other procedures may benefit from early tracheostomy. Tight tracheal and cricotracheal stenosis may require open surgery. Distal release maneuvers such as anterior-posterior tracheal release cause fewer symptoms than infrahyoid and suprahyoid release.

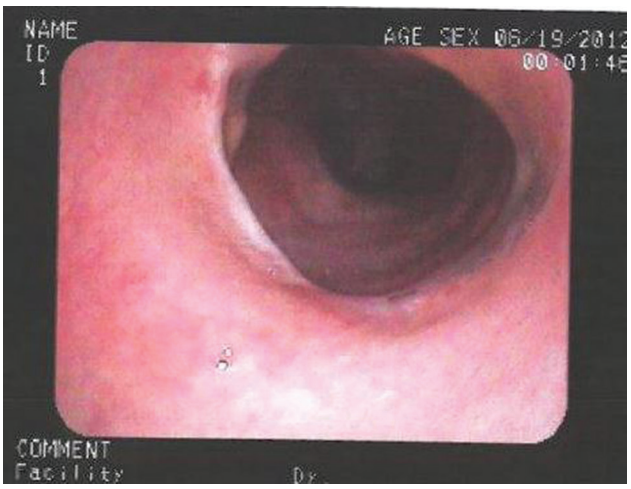

Figure 40-17. Postoperative view from clinic bronchoscopy 1 week after tracheal resection and primary anastomosis.

Case Study 40-3

Presentation

A 26-year-old Special Forces soldier who suffered a blast injury to the right neck and chest from an improvised explosive device presented with large fragment that impaled his neck (even though he was wearing a neck protector [armor]), creating a complete airway obstruction. The soldier instinctively withdrew the obstructing metal object from his neck and was able to breathe through the open laryngotracheostoma. He was intubated by his team medic through this opening and evacuated to the theater hospital, where he was found to have right neck and chest crepitus. He was stabilized following bilateral chest tube placement, and no neck exploration was initially performed. He was evacuated to the United States for definitive surgery, arriving 4 days after initial injury. Initial operative endoscopy identified no obvious laryngotracheal structures from the level of the epiglottis down to the third tracheal ring, with the anterior larynx missing.

Preoperative Work-up/Radiology

CT scan of the neck showed complete collapse of the airway. Comminuted fractures of the laryngotracheal cartilages were disorganized in the vicinity of the native larynx. Tracheostomy was high, at the level of the cricoid.

Operative Plan/Timing of Surgery

Early endoscopic and open exploration did not demonstrate any normal structures to repair. A molded ETT was placed into the presumed laryngeal structure. A multistage laryngotracheal reconstruction (LTR) was planned.

Operation

Direct laryngoscopy revealed impending complete laryngotracheal stenosis with no support from the cartilage structures still present in neck (Figure 40-18). Open laryngofissure evaluation demonstrated absent anterior cricoid ring, missing portions of the thyroid cartilage, and unrecognizable mucosa (Figures 40-19 and 40-20). The arytenoid cartilage was presumed to be intact. Open multistage LTR was performed with resection of the scar and placement of buccal mucosal graft (stage 1) with a Coe-Soft bolster (Figures 40-21, 40-22, and 40-23). The external skin was sutured to the inner mucosal lining. The Coe-Soft bolster was removed at 1 week, and the tracheostomy was left in place at the inferior aspect of the trough.

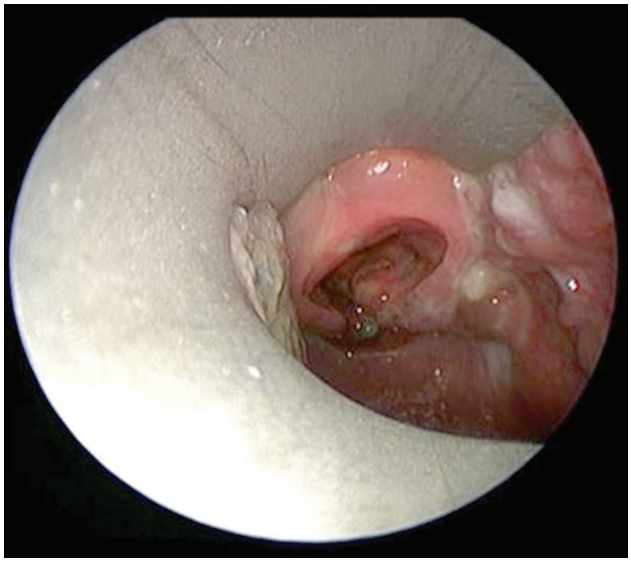

Figure 40-18. Direct laryngoscopy showing impending complete laryngotracheal stenosis with no support from the cartilage structures still present in neck.

Second-stage LTR was performed with insertion of Marlex mesh beneath the skin on the left side. Following 1 month of maturation, this skin was turned in to become the anterior laryngotracheal wall, with closure of the neck over the reconstruction (Figure 40-24).

The patient was followed for several months, and had recurrent granulomatous reactions to the mesh with limited support. The decision was made to resect the skin and mesh in favor of a structural muscular flap. The flap was constructed with a rib graft and inferiorly based sternocleidomastoid flap. This structure was sutured to the open trough to recreate the anterior laryngotracheal complex (Figures 40-25, 40-26, and 40-27).

Intraluminal inspection of the anterior airway demonstrated strong anterior support with adequate mucosal covering at 2 months. Buccal mucosal grafts created adequate vocal fold with adequate valving based upon supraglottic closure. Posterior commissure stenosis remained a concern, and it was treated by cordotomy through the reconstructed vocal fold (Figure 40-28).

Lessons Learned

The soldier was able to return to a normal diet and near normal voice but at 2 years following injury has had a persistent need for a tracheostomy or T-tube due to posterior commissure stenosis because of a high physical demand. Stage 2 failure secondary to granulation tissue along the Marlex mesh was a significant

Figure 40-19. Markings of vertical trough incision. Presumed cricoid location was inaccurate because no anterior cricoid ring was found.

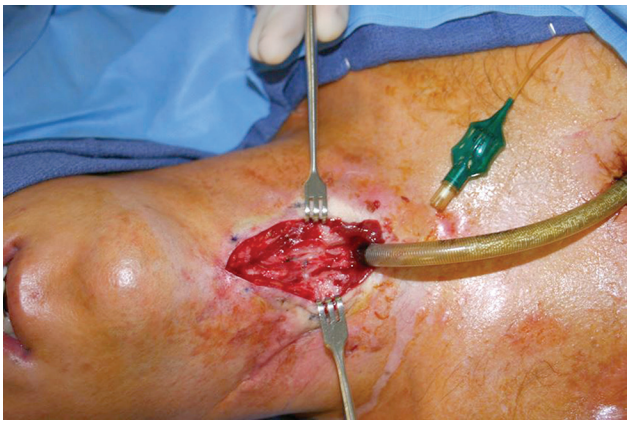

Figure 40-20. Vertical trough. Collapsed thyroid cartilage fragments identified.

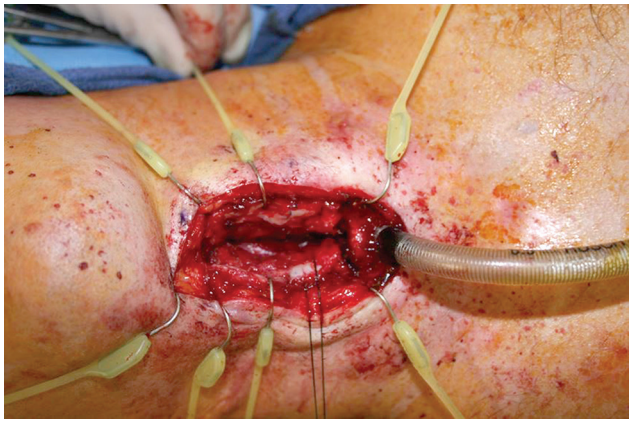

Figure 40-21. Laryngofissure performed and fragmented cartilages and mucosa sutured to the external skin, creating a trough.

Figure 40-22. Bilateral buccal mucosa was harvested. The first buccal mucosal graft is shown in place along posterior wall. Additional grafts to reconstruct the bilateral true vocal folds, portions of the vestibular folds, and trachea were performed.

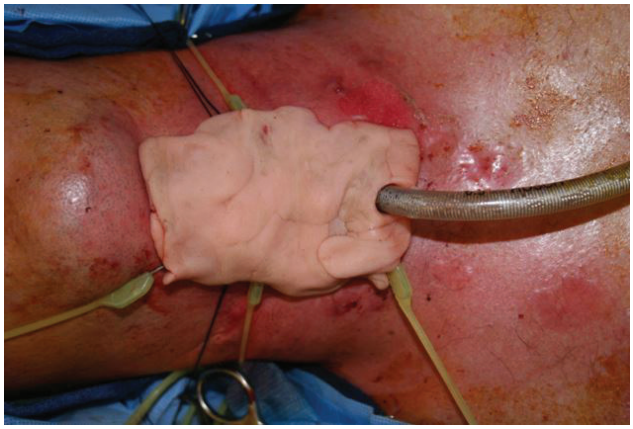

Figure 40-23. Coe-Soft bolster formed to shape of trough.

Figure 40-24. Mucosal grafts in place with bolster. The bolster was in place for 1 week and then removed, and the grafts were allowed to heal for 6 to 8 weeks.

delay to care. Use of rotational structural sternocleidomastoid flap (with an internal rib cartilage graft) proved to be a better option for this patient.

Case Study 40-4

Presentation

A 33-year-old man fell from a fifth floor window and was impaled by a fence, suffering multisystem injury with significant blood loss. He was intubated at the scene and underwent neck exploration and tracheostomy as part of his initial management. CT after hemodynamic stabilization confirmed significant laryngeal injury (Figure 40-29a,b). Fiberoptic evaluation performed at the bedside confirmed mucosal injury of the right vocal fold and ventricle (Figure 40-29c,d). The initial laryngeal repair was accomplished 48 hours after the injury. The laryngeal cartilage was approximated using PROLENE (Ethicon Inc, West Somerville, NJ) suture and midface mini-plates to create a normally contoured laryngeal framework (Figure 40-30). Endoscopic suture was performed to approximate the mucosal tear. The patient's postoperative voice was poor despite aggressive therapy.

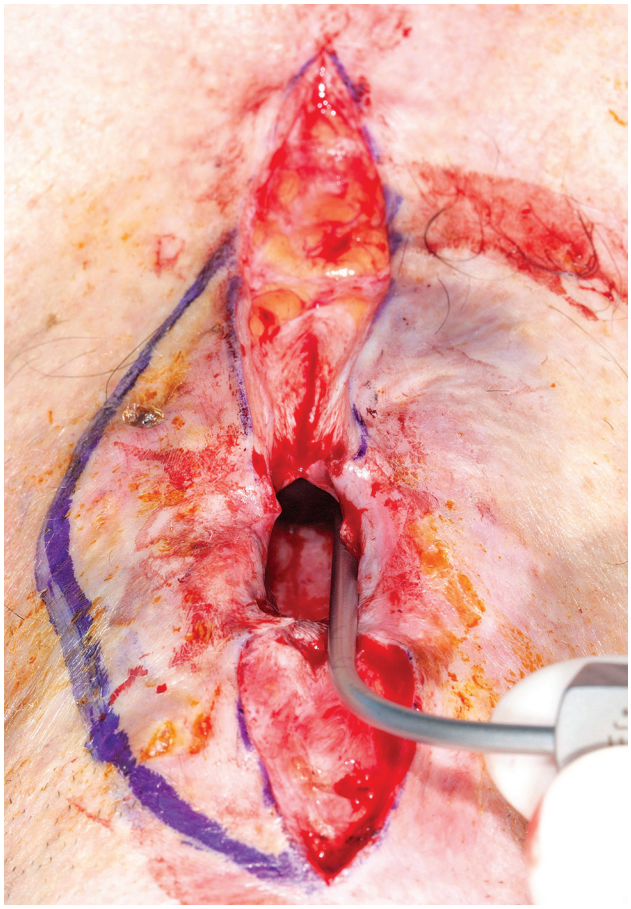

Figure 40-25. View from head; suction within the airway at level of cricoid. Markings show proposed mesh on the left side prior to inversion.

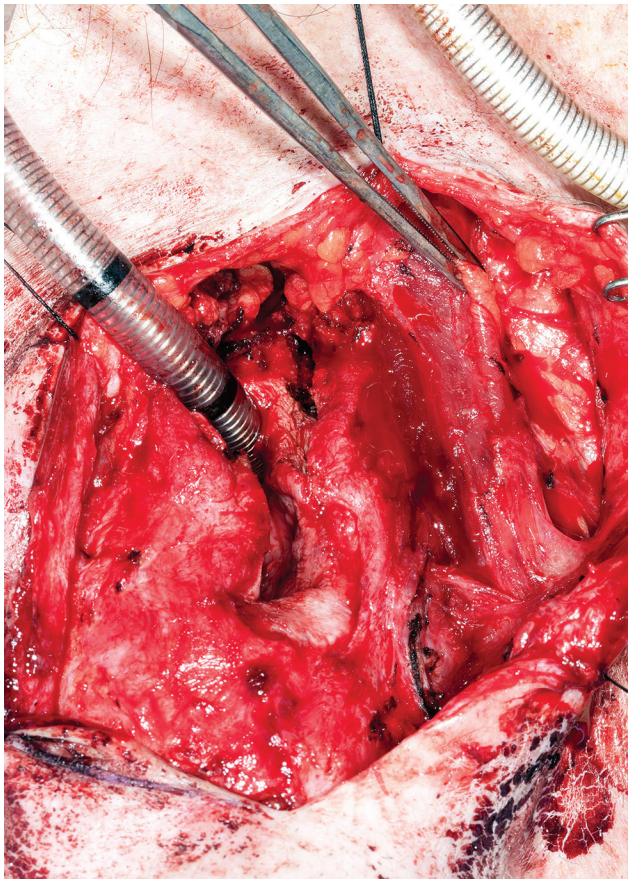

Figure 40-26. Open laryngotracheal trough with left sternocleidomastoid muscle shown in pick-up.

Preoperative Work-Up/Radiology

Stroboscopy showed an abnormal mucosal wave on the right vocal fold with the right arytenoid pulled forward. This resulted in a breathy and strained voice because the right arytenoid interfered with closure of the glottis.

Operative Planning/Timing of Surgery

Six months was allowed to pass from initial reconstruction to reoperation.

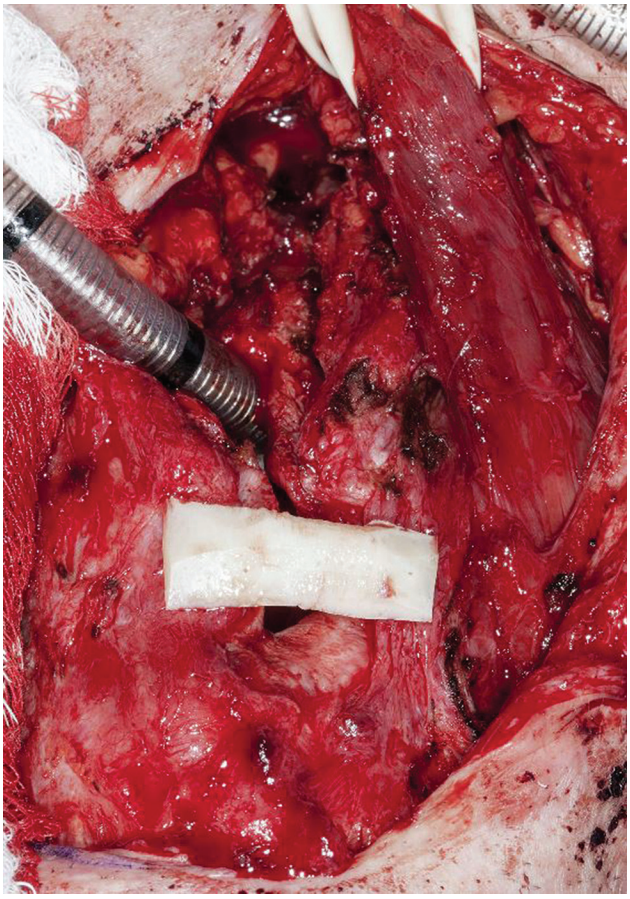

Figure 40-27. Rib graft shown in supporting position in vicinity of cricoid and anterior thyroid cartilage.

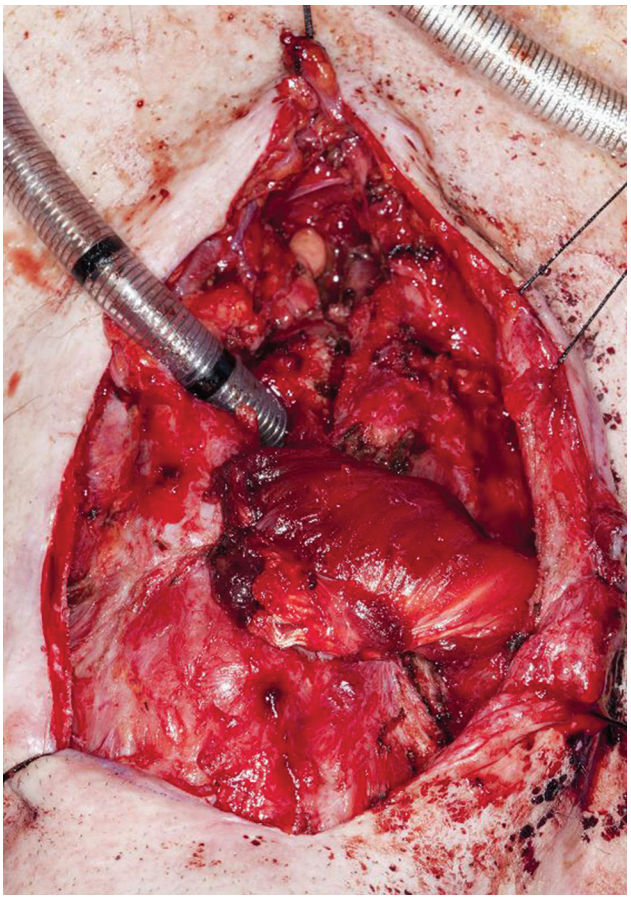

Figure 40-28. Rib graft, encased in inferiorly based sternocleidomastoid muscle flap, is sutured to cover over the laryngotracheal trough. The tracheostoma was moved to the more distal airway.

Operation

A second direct laryngoscopy in the operating room revealed a scar band retracting the right arytenoid forward. Cold dissection was performed to open the posterior portion of the right vocal fold along this scar. Scissors were used to release the scarred vocal ligament from the arytenoid. The right arytenoid returned to a normal position. A fat transplant was performed to ensure additional scarring would not form between the vocal ligament and the arytenoid (Figure 40-31).

Lessons Learned

Careful attention to anatomic reconstruction in the acute phase allowed this patient to have minimal functional limitations. Stroboscopy, voice therapy, and repeat direct laryngoscopy improved the patient's voice and quality of life.

Case Study 40-5

Presentation

A soldier in his late 20s was hit by a fragment from an improvised explosive device in the right mandibular ramus. The fragment penetrated the pharynx, injured his larynx, and exited his left neck in mid zone II. His acute treatment consisted of a mandibular repair and neck exploration. His airway was stable after extubation, and he had a weak and breathy voice. He was having difficulty swallowing liquids and frequently coughed after meals.

Preoperative Work-Up/Radiology

Full laryngeal examination in the clinic using flexible laryngoscopy with repetitive tasks[26] and rigid videostroboscopy demonstrated a healing pharyngeal wound and a lateralized left vocal process with left vocal fold

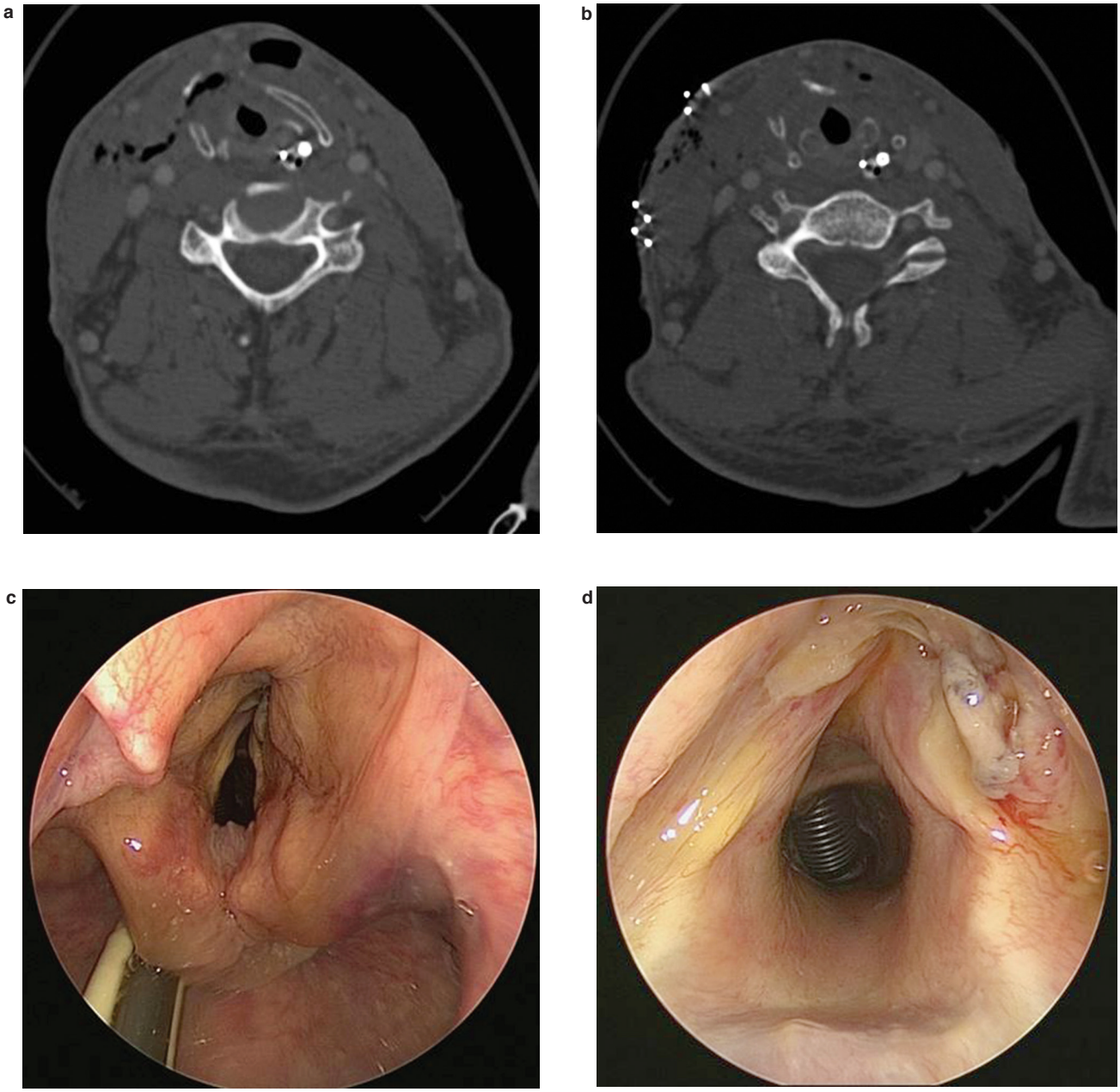

Figure 40-29. Computed tomograpy (**a, b**) and endoscopic views (**c, d**) at time of injury.

immobility, despite obvious muscular effort. An electromyography was not performed. A significant posterior glottal gap was apparent, as well as the fibrinous healing of the left arytenoid complex (Figures 40-32 and 40-33).

Operative Planning/Timing of Surgery

This patient clearly needed an arytenoid repositioning procedure with medialization laryngoplasty. To maximize his vocal outcome, the procedure was done under local anesthesia with sedation. He was treated with a course of antibiotics and a short course of steroids prior to surgery.

Operation

Left arytenoid adduction was performed in the manner described by Netterville et al.[83] Continuous transnasal laryngoscopy was utilized during medialization to provide visual cues enabling refinement of the technique. The muscular process was identified and suture was placed through it. However, the resulting

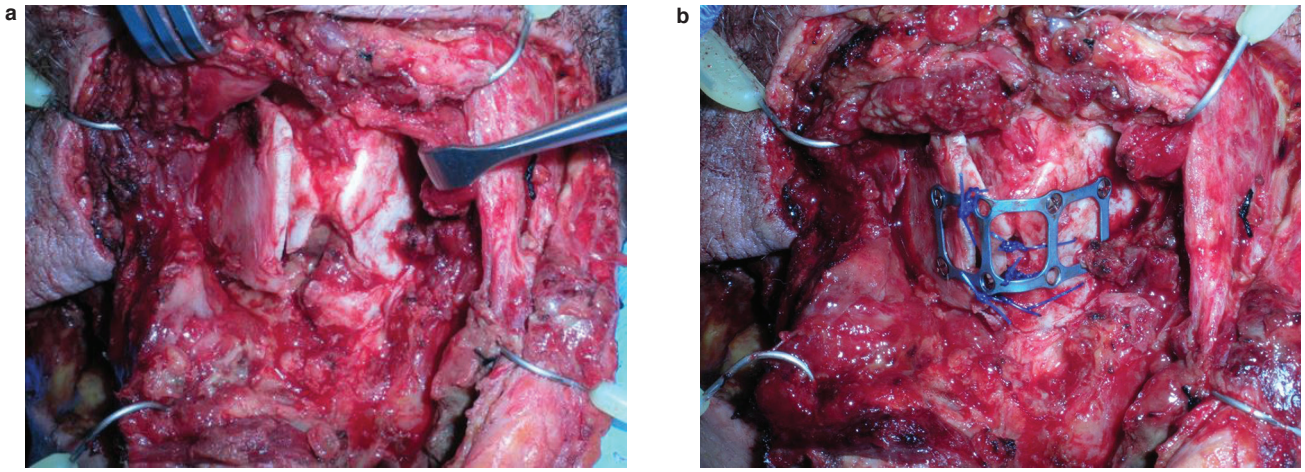

Figure 40-30. Open views before (**a**) and after (**b**) framework reconstruction. Photographs courtesy of Jared Theler, MD.

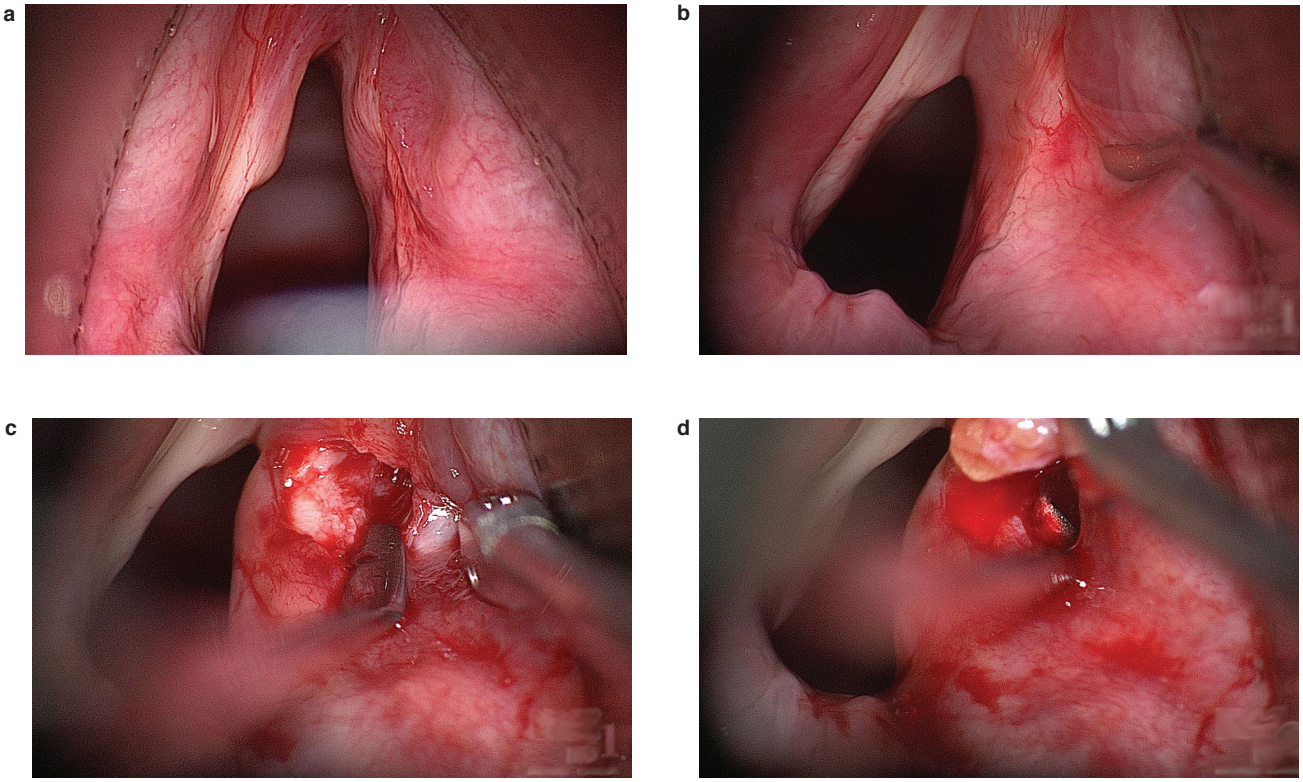

Figure 40-31. Endoscopic views of the glottis before (**a, b**) and during (**c, d**) fat transplantation.

medial movement of the vocal process was inadequate. Due to the fixed arytenoid joint, an arytenopexy using the technique described by Zeitels et al[84] was performed. The joint space was opened and the arytenoid was sutured in a medialized position. A small Gore-Tex implant was placed to support to the medialized vocal fold.

Complications

None. The patient's intraoperative and immediate postoperative voice was excellent. Unfortunately, he did not follow up after discharge from the hospital. Attempts to contact him were unsuccessful.

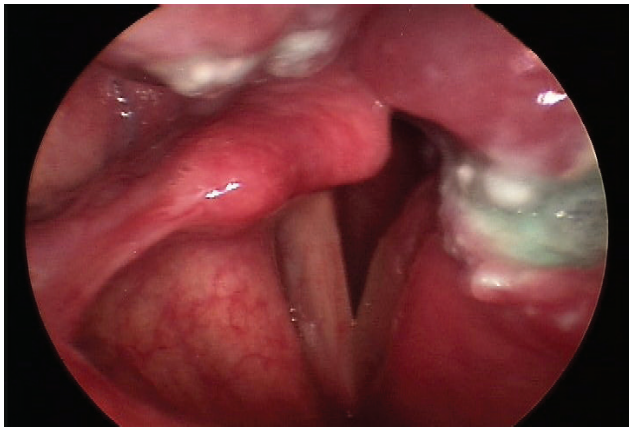

Figure 40-32. Perspective of injury from mid-pharynx: posterior pharyngeal wall injury and edema/ecchymosis/fibrinous healing of the injured left arytenoid body and aryepiglottic fold.

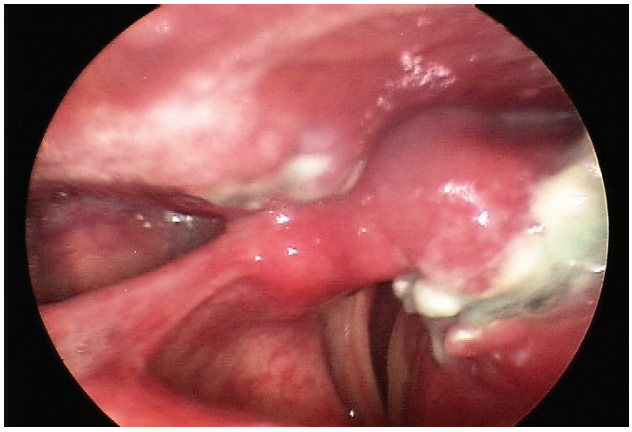

Figure 40-33. Endoscopic view within the endolarynx showing significant left vocal process lateralization.

Lessons Learned

This case was challenging due to the scarring process that was in progress from the patient's original injury. It is important to balance the benefits of early repositioning risking later changes due to scar contracture versus waiting for the scars to mature so that a more extensive operation is needed later. While a temporary injection medialization with a substance such as methylcarboxycellulose (Radiesse Voice Gel, Merz Aesthetics, San Mateo, CA) or hyaluronic acid preparation such as Restylane (Q-MED, Lausanne, Sweden) could have been performed with later repositioning, definitive management was felt to be the better choice.

Acknowledgments

We would like to acknowledge the following people for their support in writing this chapter: Gregory Dion, MD (Captain, US Army) for technical assistance; Kristen Eller, MD, and Michelle Morrison, MD (Lieutenant Commander, US Navy), for editorial oversight; and the staff of the 59th Medical Wing Medical Library for significant research assistance.

REFERENCES

1. Schaefer SD. Management of acute blunt and penetrating external laryngeal trauma. *Laryngoscope*. 2014;124:233–244.

2. Sorensen MK, Rasmussen N, Kristensen MS, et al. Laryngeal morbidity after tracheal intubation: the Endoflex(®) tube compared to conventional endotracheal intubation with stylet. *Acta Anaesthesiol Scand.* 2013;57:737–744.

3. Zias N, Chroneou A, Tabba MK, et al. Post tracheostomy and post intubation tracheal stenosis: report of 31 cases and review of the literature. *BMC Pulm Med*. 2008;8:18.

4. Colton House J, Noordzij JP, Murgia B, Langmore S. Laryngeal injury from prolonged intubation: a prospective analysis of contributing factors. *Laryngoscope*. 2010;121(3):596–600.

5. Whited RE. Posterior commissure stenosis post long-term intubation. *Laryngoscope*. 1983;93:1314–1318.

6. Freeman BD, Morris PE. Tracheostomy practice in adults with acute respiratory failure. *Crit Care Med.* 2012;40:2890–2896.

7. Kikura M, Suzuki K, Itagaki T, Takada T, Sato S. Age and comorbidity as risk factors for vocal cord paralysis associated with tracheal intubation. *Br J Anaesth*. 2007;98:524–530.

8. Zalzal GH CR. Glottic and subglottic stensosis. In: *Cummings Head and Neck Surgery.* 5th ed. Philadelphia, PA: Mosby Elsevier; 2010: 2912–2913.

9. Young D, Harrison DA, Cuthbertson BH, Rowan K, TracMan C. Effect of early vs late tracheostomy placement on survival in patients receiving mechanical ventilation: the TracMan randomized trial. *JAMA*. 2013;309:2121–2129.

10. Halum SL, Ting JY, Plowman EK, et al. A multi-institutional analysis of tracheotomy complications. *Laryngoscope*. 2012;122:38–45.

11. Lebiedz P, Suca A, Gumus E, et al. 7-year survey after percutaneous dilatational tracheotomy on a medical intensive care unit. *J Investig Med*. 2010;58:977–981.

12. Pfannenstiel TJ, Gal TJ, Hayes DK, Myers KV. Vocal fold immobility following burn intensive care. *Otolaryngol Head Neck Surg*. 2007;137:152–156.

13. Verschueren DS, Bell RB, Bagheri SC, Dierks EJ, Potter BE. Management of laryngo-tracheal injuries associated with craniomaxillofacial trauma. *J Oral Maxillofac Surg*. 2006;64:203–214.

14. Dohar JE, Greenberg LL, Galera RI. The dysphonic videolaryngoscopy with stroboscopy paradox and challenge of acquired subglottic stenosis after laryngotracheal reconstruction. *Int J Pediatr Otorhinolaryngol*. 2013;77:732–738.

15. Benjamin B. Prolonged intubation injuries of the larynx: endoscopic diagnosis, classification, and treatment. *Ann Otol Rhinol Laryngol Suppl*. 1993;160:1–15.

16. Briddell J, Mallon A, DeFatta RA, Chowdhury F, Nagorsky M. Dysphagia after strangulation. *Ear Nose Throat J.* 2012;91:E30–31.

17. Stern N, Jackson-Menaldi C, Rubin AD. Hyoid bone syndrome: a retrospective review of 84 patients treated with triamcinolone acetonide injections. *Ann Otol Rhinol Laryngol*. 2013;122:159–162.

18. Smith ME, Berke GS, Gray SD, Dove H, Harnsberger R. Clicking in the throat: cinematic fiction or surgical fact? *Arch Otolaryngol Head Neck Surg*. 2001;127:1129–1131.

19. Leonard R, Belafsky P. Dysphagia following cervical spine surgery with anterior instrumentation: evidence from fluoroscopic swallow studies. *Spine.* 2011;36:2217–2223.

20. Sinacori JT, Taliercio SJ, Duong E, Benson C. Modalities of treatment for laryngotracheal stenosis: the EVMS experience. *Laryngoscope.* 2013.

21. Maronian NC, Azadeh H, Waugh P, Hillel A. Association of laryngopharyngeal reflux disease and subglottic stenosis. *Ann Otol Rhinol Laryngol*. 2001;110:606–612.

22. Kantas I, Balatsouras DG, Kamargianis N, Katotomichelakis M, Riga M, Danielidis V. The influence of laryngopharyngeal reflux in the healing of laryngeal trauma. *Eur Arch Otorhinolaryngol.* 2009;266:253–259.

23. Yellon RF, Szeremeta W, Grandis JR, Diguisseppe P, Dickman PS. Subglottic injury, gastric juice, corticosteroids, and peptide growth factors in a porcine model. *Laryngoscope.* 1998;108:854–862.

24. Westcott CJ, Hopkins MB, Bach K, Postma GN, Belafsky PC, Koufman JA. Fundoplication for laryngopharyngeal reflux disease. *J Am Coll Surg*. 2004;199:23–30.

25. Fuller SC, Leonard R, Aminpour S, Belafsky PC. Validation of the pharyngeal squeeze maneuver. *Otolaryngol Head Neck Surg*. 2009;140:391–394.

26. Rubin AD, Praneetvatakul V, Heman-Ackah Y, Moyer CA, Mandel S, Sataloff RT. Repetitive phonatory tasks for identifying vocal fold paresis. *J Voice*. 2005;19:679–686.

27. Cohen SM, Garrett CG, Netterville JL, Courey MS. Laryngoscopy in bilateral vocal fold immobility: can you make a diagnosis? *Ann Otol Rhinol Laryngol*. 2006;115:439–443.

28. Eller RL, Livingston WJ 3rd, Morgan CE, et al. Expandable tracheal stenting for benign disease: worth the complications? *Ann Otol Rhinol Laryngol*. 2006;115:247–252.

29. Sataloff RT, Spiegel JR, Hawkshaw MJ. Strobovideolaryngoscopy: results and clinical value. *Ann Otol Rhinol Laryngol.* 1991;100:725–727.

30. Woo P, Casper J, Colton R, Brewer D. Aerodynamic and stroboscopic findings before and after microlaryngeal phonosurgery. *J Voice*. 1994;8:186–194.

31. Krishna P, Rosen CA. Office-based arytenoid palpation for diagnosis of disorders of bilateral vocal fold immobility. *Ear Nose Throat J*. 2006;85:520–522.

32. Nouraei SA, Nouraei SM, Upile T, Howard DJ, Sandhu GS. A proposed system for documenting the functional outcome of adult laryngotracheal stenosis. *Clin Otolaryngol*. 2007;32:407–409.

33. Nouraei SA, Nouraei SM, Patel A, et al. Diagnosis of laryngotracheal stenosis from routine pulmonary physiology using the "Expiratory Disproportion Index." *Laryngoscope.* 2013;123:3099–3104.

34. Carretta A, Melloni G, Ciriaco P, et al. Preoperative assessment in patients with postintubation tracheal stenosis: rigid and flexible bronchoscopy versus spiral CT scan with multiplanar reconstructions. *Surg Endosc*. 2006;20:905–908.

35. Allah MF, Hussein SR, El-Asmar AB, et al. Role of virtual bronchoscopy in the evaluation of bronchial lesions. *J Comput Assist Tomogr*. 2012;36:94–99.

36. Weiser TS, Hyman K, Yun J, Litle V, Chin C, Swanson SJ. Electromagnetic navigational bronchoscopy: a surgeon's perspective. *Ann Thorac Surg*. 2008;85:S797–S801.

37. Rubin AD, Hawkshaw MJ, Moyer CA, Dean CM, Sataloff RT. Arytenoid cartilage dislocation: a 20-year experience. *J Voice*. 2005;19:687–701.

38. Blitzer A, Crumley RL, Dailey SH, et al. Recommendations of the Neurolaryngology Study Group on laryngeal electromyography. *Otolaryngol Head Neck Surg*. 2009;140:782–793.

39. Hillel AD, Benninger M, Blitzer A, et al. Evaluation and management of bilateral vocal cord immobility. *Otolaryngol Head Neck Surg*. 1999;121:760–765.

40. Guyton DC, Barlow MR, Besselievre TR. Influence of airway pressure on minimum occlusive endotracheal tube cuff pressure. *Crit Care Med*. 1997;25:91–94.

41. Hess DR. Tracheostomy tubes and related appliances. *Respir Care*. 2005;50:497–510.

42. Ford CN, Inagi K, Khidr A, Bless DM, Gilchrist KW. Sulcus vocalis: a rational analytical approach to diagnosis and management. *Ann Otol Rhinol Laryngol*. 1996;105:189–200.

43. Allen J. Cause of vocal fold scar. *Curr Opin Otolaryngol Head Neck Surg*. 2010;18:475–480.

44. Lim X, Tateya I, Tateya T, Munoz-Del-Rio A, Bless DM. Immediate inflammatory response and scar formation in wounded vocal folds. *Ann Otol Rhinol Laryngol*. 2006;115:921–929.

45. Oosthuizen JC, Burns P, Russell JD. Endoscopic management of posttraumatic supraglottic stenosis in the pediatric population. *Am J Otolaryngol*. 2011;32:426–429.

46. Stevens MS, Chang A, Simpson CB. Supraglottic stenosis: etiology and treatment of a rare condition. *Ann Otol Rhinol Laryngol*. 2013;122:205–209.

47. Perkins JA, Inglis AF Jr, Richardson MA. Iatrogenic airway stenosis with recurrent respiratory papillomatosis. *Arch Otolaryngol Head Neck Surg*. 1998;124:281–287.

48. Walner DL, Holinger LD. Supraglottic stenosis in infants and children. A preliminary report. *Arch Otolaryngol Head Neck Surg*. 1997;123:337–341.

49. Rutter MJ, Link DT, Hartley BE, Cotton RT. Arytenoid prolapse as a consequence of cricotracheal resection in children. *Ann Otol Rhinol Laryngol*. 2001;110:210–214.

50. Krishna PD, Malone JP. Isolated adult supraglottic stenosis: surgical treatment and possible etiologies. *Am J Otolaryngol*. 2006;27:355–357.

51. Bogdasarian RS, Olson NR. Posterior glottic laryngeal stenosis. *Otolaryngol Head Neck Surg*. 1980;88:765–772.

52. Rosen C, Simpson B. *Operative Techniques in Laryngology*. Berlin-Heidelberg, Germany: Springer-Verlag, 2008.

53. Deganello A, Gallo O, Gitti G, de'Campora E, Mahieu H. New surgical technique for endoscopic management of anterior glottic web. *B-ENT*. 2010;6:261–264.

54. Schweinfurth J. Single-stage, stentless endoscopic repair of anterior glottic webs. *Laryngoscope.* 2002;112:933–935.

55. McCaffrey TV. Classification of laryngotracheal stenosis. *Laryngoscope*. 1992;102:1335–1340.

56. McCaffrey TV. Management of laryngotracheal stenosis on the basis of site and severity. *Otolaryngol Head Neck Surg*. 1993;109:468–473.

57. Nouraei SA, Sandhu GS. Outcome of endoscopic resection tracheoplasty for treating lambdoid tracheal stomal stenosis. *Laryngoscope.* 2013;123:1735–1741.

58. Clement P, Hans S, de Mones E, Sigston E, Laccourreye O, Brasnu D. Dilatation for assisted ventilation-induced laryngotracheal stenosis. *Laryngoscope*. 2005;115:1595–1598.

59. Herrington HC, Weber SM, Andersen PE. Modern management of laryngotracheal stenosis. *Laryngoscope*. 2006;116:1553–1557.

60. Mandour M, Remacle M, Van de Heyning P, Elwany S, Tantawy A, Gaafar A. Chronic subglottic and tracheal stenosis: endoscopic management vs. surgical reconstruction. *Eur Arch Otorhinolaryngol*. 2003;260:374–380.

61. Laccourreye O, Brasnu D, Seckin S, Hans S, Biacabe B, Laccourreye H. Cricotracheal anastomosis for assisted ventilation-induced stenosis. *Arch Otolaryngol Head Neck Surg*. 1997;123:1074–1077.

62. Ahn SH, Sung MW, Kim KH. Factors associated with staged reconstruction and successful stoma closure in tracheal resection and end-to-end anastomosis. *Arch Otolaryngol Head Neck Surg*. 2004;130:57–62.

63. Fairchild F. Reconstruction of the trachea. *J Surg Gynecol Obstet*. 1927;44:119–122.

64. Som ML. Reconstruction of the larynx and the trachea; report of a case of extensive cicatrical stenosis. *J Mount Sinai Hosp*. 1951;17:1117–1126.

65. Biller HF, Lawson W, Weisberg V. Staged repair of extensive tracheal and laryngotracheal stenoses. *Ann Otol Rhinol Laryngol*. 1986;95:586–589.

66. Isshiki N, Taira T, Nose K, Kojima H. Surgical treatment of laryngeal web with mucosa graft. *Ann Otol Rhinol Laryngol*. 1991;100:95–100.

67. Yellon RF. Totally obstructing tracheotomy-associated suprastomal granulation tissue. *Int J Pediatr Otorhinolaryngol*. 2000;53:49–55.

68. Gallagher TQ, Hartnick CJ. Suprastomal granuloma. *Adv Otorhinolaryngol*. 2012;73:63–65.

69. Gupta A, Cotton RT, Rutter MJ. Pediatric suprastomal granuloma: management and treatment. *Otolaryngol Head Neck Surg*. 2004;131:21–25.

70. Ismail-Koch H, Vilarino-Varela J, Harker H, Hore I. The use of endotracheal tubes in the excision of troublesome paediatric suprastomal granulomas. *Clin Otolaryngol*. 2011;36:403–404.

71. Prescott CA. Factors that influence successful decannulation after surgery for laryngo-tracheal stenosis in children. *Int J Pediatr Otorhinolaryngol*. 1994;30:183–188.

72. Raghuraman G, Rajan S, Marzouk JK, Mullhi D, Smith FG. Is tracheal stenosis caused by percutaneous tracheostomy different from that by surgical tracheostomy? *Chest*. 2005;127:879–885.

73. Epstein SK. Late complications of tracheostomy. *Respir Care*. 2005;50:542–549.

74. Sanchez MO, Greer MC, Masters IB, Chang AB. A comparison of fluoroscopic airway screening with flexible bronchoscopy for diagnosing tracheomalacia. *Pediatr Pulmonol*. 2012;47:63–67.

75. Chen G, Wang Z, Liang X, et al. Treatment of cuff-related tracheal stenosis with a fully covered retrievable expandable metallic stent. *Clin Radiol*. 2013;68:358–364.

76. Jones LM, Mair EA, Fitzpatrick TM, Lyon RD, Feuerstein IM. Multidisciplinary airway stent team: a comprehensive approach and protocol for tracheobronchial stent treatment. *Ann Otol Rhinol Laryngol*. 2000;109:889–898.

77. Mair EA. Caution in using subglottic stents for Wegener's granulomatosis. *Laryngoscope*. 2004;114:2060–2061; author reply 2061.

78. Montgomery J, Sau C, Clement W, et al. Treatment of tracheomalacia with aortopexy in children in Glasgow. *Eur J Pediatr Surg*. 2013;Aug 5. [Epub ahead of print]

79. Cho JH, Kim H, Kim J. External tracheal stabilization technique for acquired tracheomalacia using a tailored silicone tube. *Ann Thorac Surg*. 2012;94:1356–1358.

80. Gobel G, Karaiskaki N, Gerlinger I, Mann WJ. Tracheal ceramic rings for tracheomalacia: a review after 17 years. *Laryngoscope*. 2007;117:1741–1744.

81. Hagl S, Jakob H, Sebening C, et al. External stabilization of long-segment tracheobronchomalacia guided by intraoperative bronchoscopy. *Ann Thorac Surg*. 1997;64:1412–1420; discussion 1421.

82. Anton-Pacheco JL, Villafruela M, Lopez M, Garcia G, Luna C, Martinez A. Surgical management of severe suprastomal cricotracheal collapse complicating pediatric tracheostomy. *Int J Pediatr Otorhinolaryngol.* 2008;72:179–183.

83. Netterville JL, Stone RE, Luken ES, Civantos FJ, Ossoff RH. Silastic medialization and arytenoid adduction: the Vanderbilt experience. A review of 116 phonosurgical procedures. *Ann Otol Rhinol Laryngol.* 1993;102:413–424.

84. Zeitels SM, Mauri M, Dailey SH. Adduction arytenopexy for vocal fold paralysis: indications and technique. *J Laryngol Otol*. 2004;118:508–516.